

HEREDITARY PALMOPLANTAR KERATODERMA ASSOCIATED WITH PRIMARY (CONGENITAL) LYMPHEDEMA

S.O. Ogunbiyi, J. Deguara, C. Moss, K.G. Burnand

Department of Academic Surgery, St Thomas' Hospital, London and Department of Dermatology,
Birmingham Children's Hospital, Birmingham, UK

ABSTRACT

The palmoplantar keratodermas are a heterogenous group of hereditary disorders of keratinization. They are characterized by epidermal thickening and a yellow waxy appearance of the palms and soles. Genetic studies have linked various forms of palmoplantar keratoderma to markers on chromosomes one, twelve, and seventeen, and several genes have been identified. Primary lymphedema is occasionally present at birth (congenital lymphedema or Milroy's disease), but more commonly develops at puberty (lymphedema praecox). Genetic studies have linked various autosomal dominant forms of primary lymphedema (Milroy's disease and lymphedema distichiasis), to genes on chromosomes five and sixteen respectively. We report a case of palmoplantar keratoderma in a child with congenital lymphedema. To our knowledge, this has not been previously described and may represent a new phenotype for future genetic study.

Keywords: palmoplantar keratoderma, congenital lymphedema, lymphedema genes

CASE REPORT

A 30-month old boy presented with a history (from birth) of unilateral lower limb swelling over the dorsal aspect of his right

foot. He had no family history of lymphedema, but there was a strong family history of yellow palms and feet. Other family members with yellow palms and feet included his paternal great-grandmother and grandmother, his father, two paternal aunts, and his female sibling (*Fig. 1*).

Examination revealed a healthy looking child with mild swelling of the right leg and yellow palms and soles (*Figs. 2A and 2B*). His father had similarly colored hands and feet with associated thickening (*Fig. 2B*). The child had no other congenital abnormalities.

An abdominal ultrasound scan, thyroid, liver, and renal function tests performed within a few days of birth were all normal. The child's father had previously undergone a punch biopsy from the sole of his foot and a blood sample had been taken for histology and genetic studies. Histology confirmed epidermolytic palmo-plantar keratoderma, with hyperkeratosis, epidermolysis, and prominent clumping of kerato-hyaline granules. DNA analysis of the child's blood did not demonstrate any mutation in the keratin 9 gene (associated with certain types of palmo-plantar keratoderma) or the vascular endothelial growth factor receptor three (VEGFR-3) gene (associated with Milroy's disease).

The child was placed on regular follow-up to monitor the progress of the right limb lymphedema.

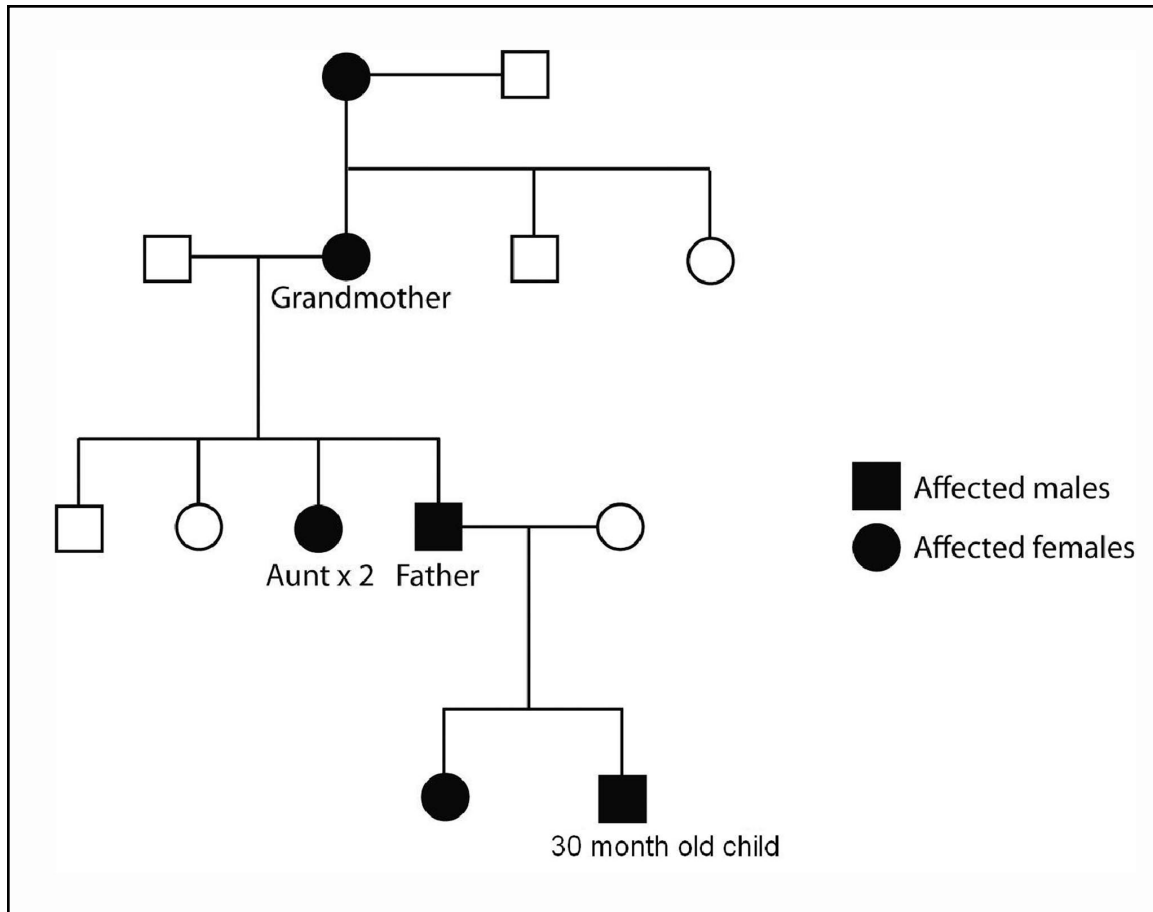


Fig. 1. Family tree of 30-month old child showing autosomal dominant pattern of inheritance of yellow palms and feet.

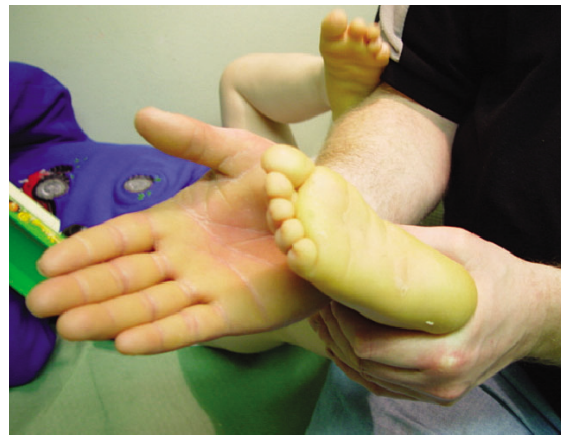
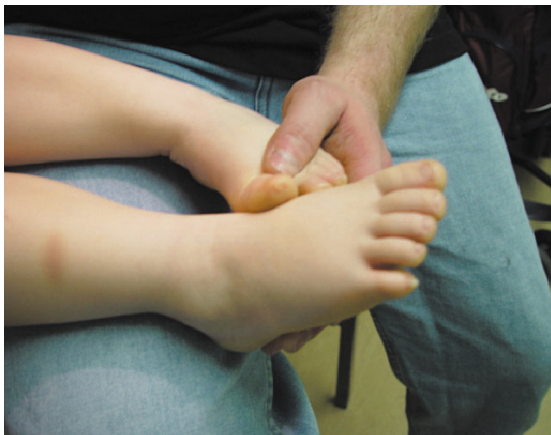
Fig. 2. A – Right lower limb lymphedema in a 30-month old child. B – Yellow soles of feet in 30-month old child, and yellow palm in father.

DISCUSSION

Palmoplantar keratoderma (PPK) was first described by Thost (1), and is characterized by hyperkeratosis of the palms and soles (2). It has either an autosomal dominant or recessive pattern of inheritance, and genetic studies have linked various forms of it to mutations on chromosomes one (3), four (4), eight (5), twelve (6), and thirteen (7). A form of PPK associated with right ventricular cardiomyopathy and woolly hair has also been mapped to chromosome seventeen (8).

The epidermolytic variant of hereditary PPK seen in this family was described by Vorner (9) and is usually an autosomal dominant disorder associated with mutations in the keratin 9 gene (KRT9) (10,11). Genetic analysis of skin from the father did not reveal any mutations in the keratin 9 gene.

The child in this case presented with congenital lymphedema of a Milroy's disease phenotype. It was noticed at birth to preferentially affect the right lower extremity, and foot. There was, however, no family history of lymphedema and genetic screening for VEGFR-3 mutation was negative.

This child may have two separate congenital abnormalities or the lymphedema may be part of a new single gene abnormality causing lymphedema and skin abnormalities. Hereditary lymphedema is known to occur as part of lymphedema angiodyplasia (LE-AD) syndromes with congenital lymphedema associated with central nervous system, ocular, pulmonary, or other congenital abnormalities.

This case raises the possibility that primary, congenital lymphedema may, in some cases, be associated with palmoplantar keratoderma. Further genetic analysis and additional case are indicated.

REFERENCES

1. Thost, A: Ueber erbliche Ichthyosis et plantaris cornea. 1880.
2. Sehgal, VN, K Kumar, S Narayan: Hereditary palmoplantar keratoderma (four cases in three generations). *Int. J. Dermatol.* 40 (2001), 130-132.
3. Richard, G, JP Lin, L Smith, et al: Linkage studies in erythrokeratodermias: fine mapping, genetic heterogeneity and analysis of candidate genes. *J. Invest. Dermatol.* 109 (1997), 666-671.
4. Lee, YA, HP Stevens, E Delaporte, et al: A gene for an autosomal dominant sclero-atrophic syndrome predisposing to skin cancer (Huriez syndrome) maps to chromosome 4q23. *Am. J. Hum. Genet.* 66 (2000), 326-330.
5. Fischer, J, B Bouadjar, R Heilig, et al: Genetic linkage of Meleda disease to chromosome 8qter. *Eur. J. Hum. Genet.* 6 (1998), 542-547.
6. Kelsell, DP, HP Stevens, R Ratnavel, et al: Genetic linkage studies in non-epidermolytic palmoplantar keratoderma: evidence for heterogeneity. *Hum. Mol. Genet.* 4 (1995), 1021-1025.
7. Maestrini, E, BP Korge, J Ocana-Sierra, et al: A missense mutation in connexin26, D66H, causes mutilating keratoderma with sensorineural deafness (Vohwinkel's syndrome) in three unrelated families. *Hum. Mol. Genet.* 8 (1999), 1237-1243.
8. Coonar, AS, N Protonotarios, A Tsatsopoulou, et al: Gene for arrhythmogenic right ventricular cardiomyopathy with diffuse nonepidermolytic palmoplantar keratoderma and woolly hair (Naxos disease) maps to 17q21. *Circulation* 97 (1998), 2049-2058.
9. Vorner, H: Zur Kenntniss des keratoma hereditarium palmare et plantare. *Arch. Derm. Syph.* 56 (1901), 3-31.
10. Hennies, HC, D Zehender, J Kunze, et al: Keratin 9 gene mutational heterogeneity in patients with epidermolytic palmoplantar keratoderma. *Hum. Genet.* 93 (1994), 649-654.
11. Reis, A, HC Hennies, L Langbein, et al: Keratin 9 gene mutations in epidermolytic palmoplantar keratoderma (EPPK). *Nat. Genet.* 6 (1994), 174-179.

S.O. Ogunbiyi
Surgical Registrar
Dumfries and Galloway Royal Infirmary
Bankend Road, Dumfries.
DG1 4AP, UK
E-mail: samuelogunbiyi@gmail.com