

INTERSTITIAL MAGNETIC RESONANCE LYMPHOGRAPHY: THE CLINICAL EFFECTIVENESS OF A NEW METHOD

E. Dimakakos, A. Koureas, V. Koutoulidis, V. Skiadas, K. Katsenis,
N. Arkadopoulos, A. Gouliamos, L. Vlachos

Vascular Unit of 2nd Surgical Clinic (ED, KK, NA), University of Athens; A' Dept. of Radiology (AK, VK, VS, LV), Areteio University Hospital; B' Dept. of Radiology (AG), Attiko University Hospital; Athens, Greece

ABSTRACT

The aim of this study is to evaluate effectiveness of interstitial magnetic resonance lymphography as an examination for the depiction of the lymphatic system in humans by comparison with direct x-ray lymphography. We studied 14 subjects (two volunteers and 12 patients with clinical suspicion of lymphedema of the lower extremities). We first administered subcutaneous gadobutrol between the toes and performed MR lymphography. After seven days, we injected lipiodol into the lymph vessels of 8 patients and performed x-ray direct lymphography to compare findings of two methods. We identified the normal lymphatic system (lymph vessels and inguinal lymph nodes) of volunteers. In seven subjects, we were able to image an abnormal lymphatic system with decreased number of lymph vessels, lymphoceles, and ectatic lymph vessels. In three subjects we identified both an abnormal lymphatic and venous system and in two patients only the venous system. In all cases x-ray direct lymphography confirmed the findings of the MR lymphography. No side effects were observed from either contrast agent. We expect that in the future, interstitial MR lymphography will be improved and evolve into a valuable diagnostic tool for the evaluation of lymphatic diseases particularly those who present with primarily lymphedema

in the lower limbs or second, in regions other than extremities.

Keywords: interstitial magnetic resonance lymphography, gadobutrol, lymphedema, lymphography

Many patients worldwide suffer from lymphatic diseases and in particular lymphedema. Sometimes it is very difficult to determine the correct diagnosis of a lymphatic disorder especially when it is at very early stages or when it is primary in nature (1). It is very important for the physician to know the anatomic/functional status of the lymphatic system for determining prognosis and selecting appropriate treatment. Multiple tools are available including history, clinical examination, blood tests, and imaging tests. Imaging tests for the diagnosis of lymphatic disease were introduced in 1952 when Kinmonth first presented x-ray direct lymphography (2). Due to some adverse effects (emboli, wound inflammation, allergic reactions), x-ray direct lymphography has been replaced with other imaging exams such as indirect lymphography, ultrasound, computed tomography, lymphoscintigraphy and magnetic resonance imaging (3,4). Lymphoscintigraphy is currently the best method for the depiction of the lymphatic system according to the

TABLE 1
Demographic and Clinical Characteristics of Patients and Healthy Volunteers

N	Gender	Age (years)	Weight (Kg)	Lymphedema /stage	Duration of disease (years)
1	Male	65	77	—	—
2	Male	52	81	—	—
3	Male	60	79	Both legs / Stage I	5
4	Female	28	82	Both legs / Stage I	3
5	Female	37	98	Both legs / Stage II	15
6	Female	58	64	Both legs / Stage II	22
7	Female	36	65	Left leg / Stage I	15
8	Male	20	70	Left leg / Stage I	0.7
9	Male	16	65	Left leg / Stage I	6
10	Male	17	77	Left leg / Stage I	11
11	Male	26	76	Right leg / Stage I	05
12	Male	51	86	Left leg / Stage II	11
13	Female	10	28	Right leg / Stage I	04
14	Female	66	64	Right Leg / Stage II	15

International Society of Lymphology (5). However, this technique has several disadvantages such as lack of established protocols for dosage or technique of the administration and a reported high false negative rate by some investigators (6). These disadvantages prompted investigators to look for other tests with fewer complications and equally high diagnostic value. For these reasons, different agents have been tested either intravenously or subcutaneously for magnetic resonance (MR) lymphography with different results (7-14). Gadobutrol (Gadovist, Shering) is a paramagnetic contrast agent that has been used intravenously in humans and subcutaneously in rats and in rabbits without serious adverse reactions (15-20). The purpose of this study is to evaluate the subcutaneous administration of Gadobutrol contrast agent for the depiction of the lymphatic system (vessels and lymph nodes) in humans with Magnetic Tomography and to compare the results with classical x-ray lymphography.

MATERIAL AND METHODS

Following approval of the research protocol by the Ethical Committee of the 'Areteion' University Hospital of Athens, we administered gadobutrol in fourteen human subjects (two healthy volunteers and twelve patients with clinical suspicion of lymphedema) (Table 1). Inclusion criteria consisted of: a) willingness to participate; b) signing of an informed consent form; c) absence of allergic history; d) absence of pregnancy; and e) absence of contraindications to undergo an MRI (e.g. pacemaker). We used gadobutrol, which is a commercially available extracellular, water-soluble paramagnetic contrast agent without inflammatory reactions in animals (19,20) and without nephrotoxic and anaphylactoid reactions in humans (15,18).

Subjects were classified according to clinical stage of lymphedema (stages 0, I, II, III) (20). All subjects underwent color duplex of veins of the lower extremities. Three subjects were found to have chronic venous

TABLE 2
Imaging Results

Subjects	LE Presentation	IMRL Results	Lymphography Results	Figure
1,2	Control	Inguinal vessels and nodes	n.d.	1
3 M	Bilateral Lower LE	To knee on R, to inguinal nodes on L	same	2
4 F	Bilateral LLE	To below inguinal nodes	same	
5 F	Bilateral LLE	Venous system only	n.d.	
6F	Bilateral LLE	To inguinal nodes with reduced vessels	same	
7 F	LLLE	Venous system only	only one lymph vessel	5
8 M	LLLE	To inguinal nodes with one lymph vessel	same	3
9 M	LLLE	Only to knee with reduced vessels and small lymphocele	same	
10 M	RLLE	To inguinal nodes with one lymph vessel	same	4
11 M	LLLE	To inguinal nodes and ectactic vessel	same	
12 M	LLLE	To inguinal nodes with reduced vessels	n.d.	6
13 F	RLLE	To inguinal nodes with reduced vessels	n.d.	
14 F	RLLE	To knee and lymphocele to mid-calf on R and with reduced vessels on L	n.d.	

insufficiency, and the rest presented with no vascular disorders in their limbs. We administered in each limb 5 ml of a solution containing 4.5 ml gadobutrol and 0.5 ml hydrochloride lidocaine. We prepared the mixture by drawing into a 5 ml syringe, 4.5 ml of commercial gadobutrol, and then with the same syringe, we pulled 0.5 ml of hydrochloride lidocaine (2%, 20mg/ml,

AstraZeneca, Monts, France). About one ml of solution was administered subcutaneously in the dorsal area of the foot and in each skinfold between the toes using a 26 gauge needle. Immediately after the administration, local massage was performed for five minutes and MR imaging was obtained at 5, 10, 15, 30, 45, 60, 90 and 120 minutes at the levels of the foot, calves and the pelvis. We checked

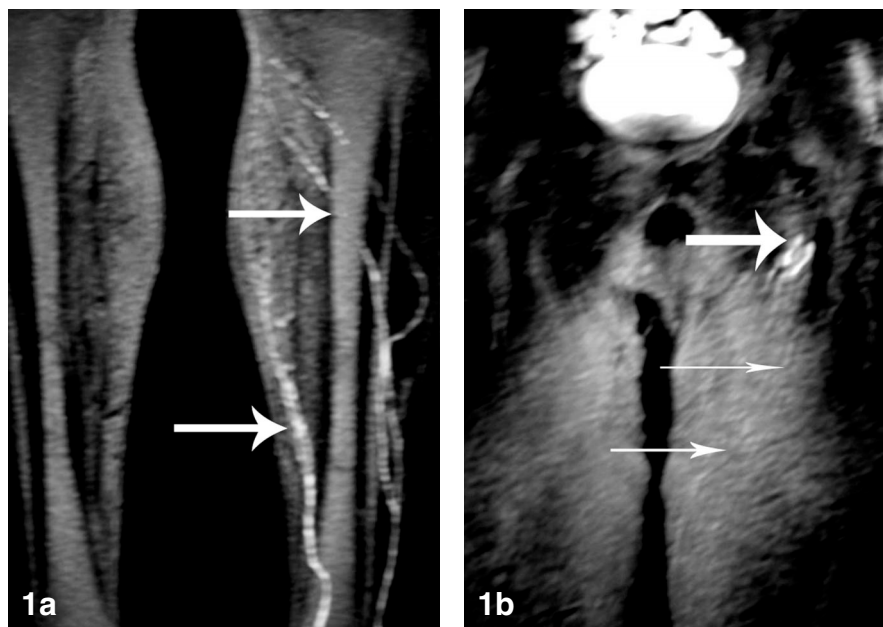


Fig 1. a,b) Depiction of lymph vessels (long white arrows) and inguinal lymph nodes (short white arrow) in control subject (No. 1 from Table 1) after subcutaneous administration of gadobutrol (IMRL).

all individuals during the examination and then daily for at least seven days in order to detect any side effects such as pain and edema of the injection site or other anaphylactic reactions.

MR imaging was performed with a Philips 1.5 -T system and the lymphatic system was depicted with sequence as T1W 3D gradient echo TR/TE 4.8 msec/1.4 msec, flip angle: 30°, FOV 179x512.

Seven days after interstitial MR lymphography, we performed direct x-ray lymphography in 8 of 12 subjects by administering an iodinated contrast agent (lipiodol) directly into a peripheral pedal lymph vessel. We made an incision to expose a peripheral lymphatic vessel and placed a catheter to infuse the lipiodol at 6 ml per hour. X-rays were obtained successively 5, 10, 20, 30, 45, 60, 90, 120 minutes after contrast administration. We compared results of direct x-ray lymphography with MR lymphography. All subjects were examined for an additional seven days to detect any side effects.

RESULTS

Following subcutaneous injection of Gadobutrol, both control subjects demonstrated a MR lymphography which included depiction of normal lymph vessels and inguinal lymph nodes (*Fig. 1*). In subjects with suspicion of lymphedema, we succeeded in imaging the lymphatic system in 10 of 12 subjects (in the other two, we only depicted the venous system). The results for individual subjects are tabulated in *Table 2* (see also *Figs. 2-6*).

Overall, direct x-ray lymphography in 8 subjects confirmed findings of the previous IMR lymphography in the same patients. In volunteers and subjects, the depiction of the lymphatic system required 60-90 minutes with MR lymphography to the inguinal lymph nodes, whereas with direct lymphography it required about 30 minutes. During the injection of Gadobutrol, mild pain of 2-3 minutes duration was present in all individuals. All the subjects could walk and go home

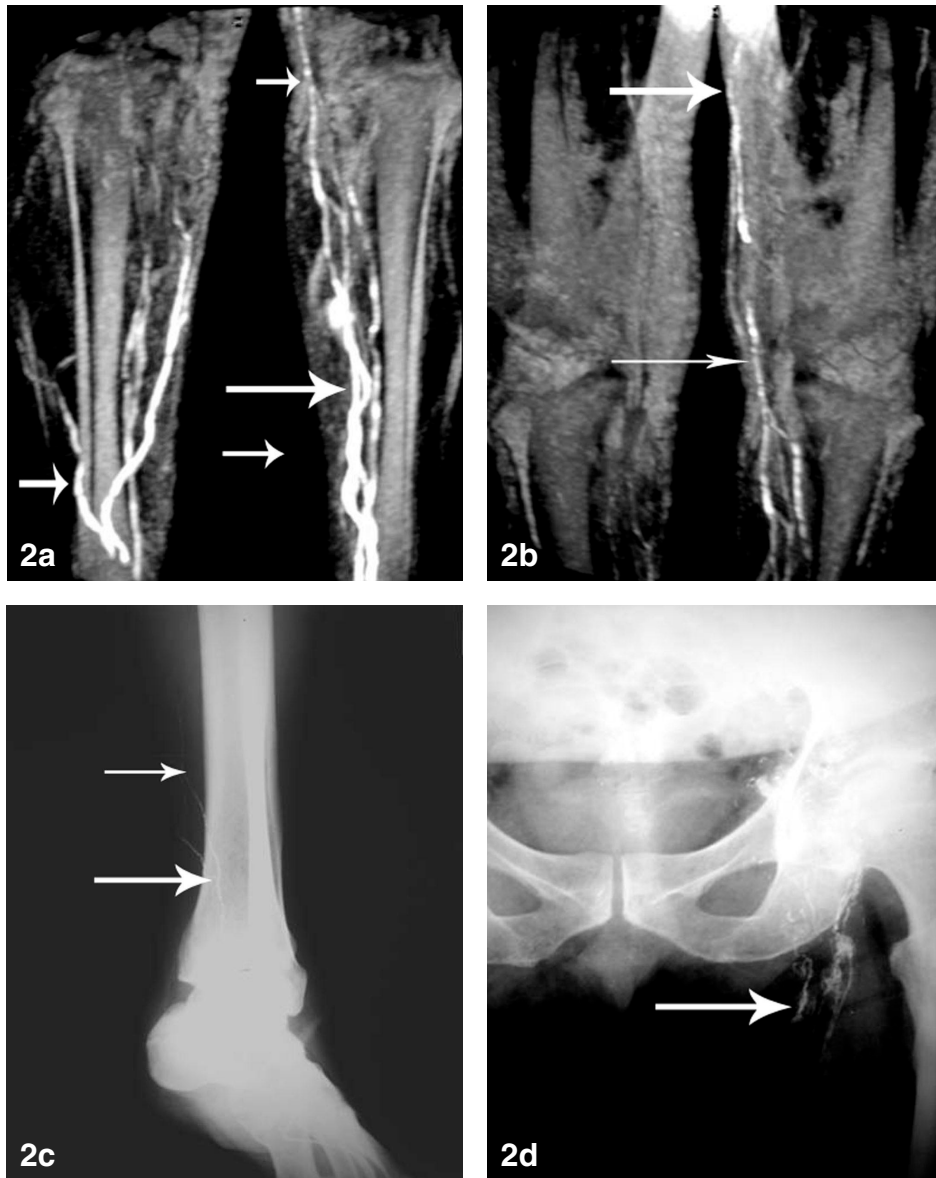


Fig 2. Decreased number of lymph vessels (white arrows) in both legs seen by IMRL (a,b) and confirmed by direct x-ray lymphography (c,d) in a subject with lymphedema (No. 3 from Table 1).

immediately after the end of both examinations. During the seven-day period after the administration of both contrast agents, we did not record any adverse reactions.

DISCUSSION

Obtaining a specific diagnosis of lymphatic disease is important to determine prognosis, choose optimal method of therapy, and possibly prevent serious complications. Imaging of the functional lymphatic system is an integral component of this assessment. Despite the success of imaging for the

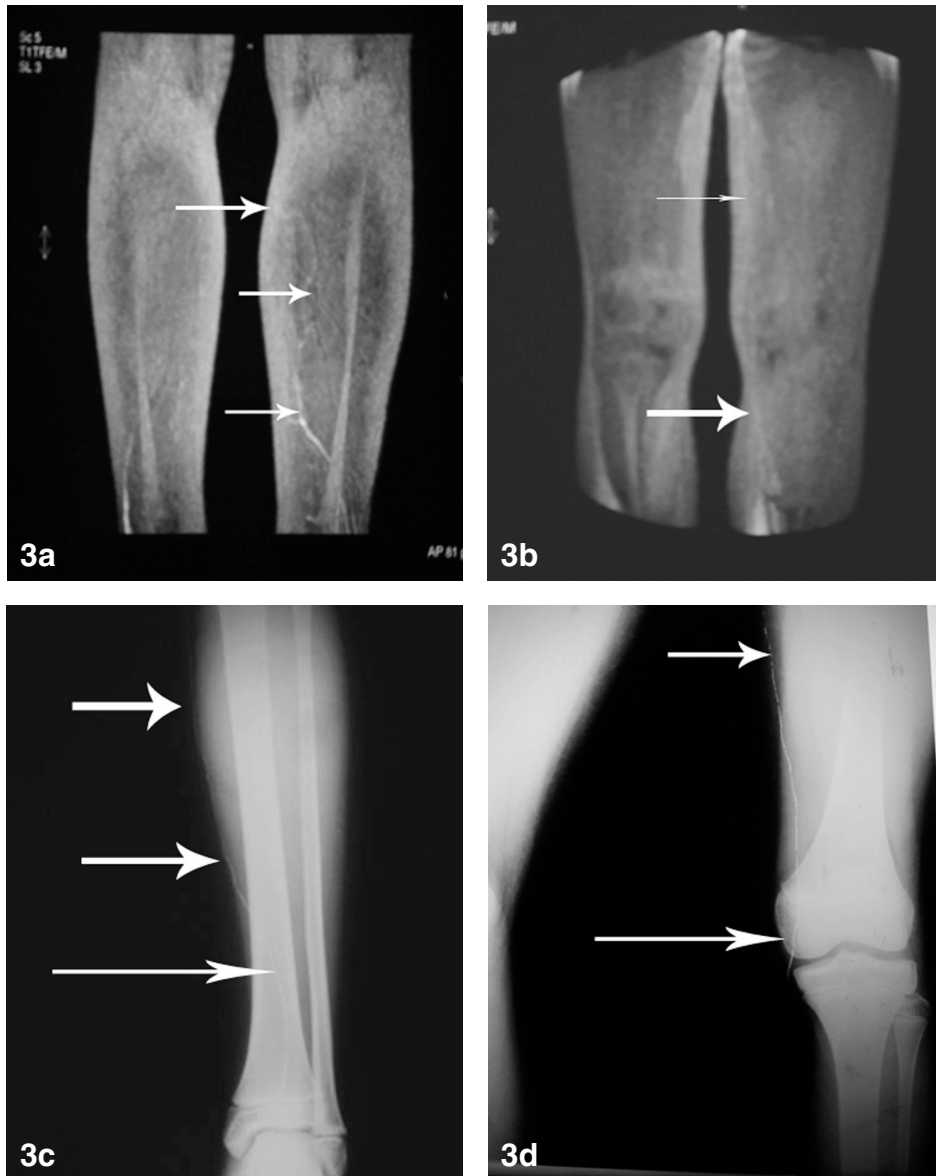


Fig 3. Depiction of a single lymphatic vessel (white arrows) in IMPRL (a,b) which was confirmed by direct x-ray lymphography (c,d) in a subject with lymphedema (No 8. from Table 1).

lymphatic system to date, an elusive goal has been a method(s) for differential diagnosis of a metastatic lymph node (3,15,20,21). In this work, we studied the efficiency of gadobutrol as a subcutaneous contrast agent for MRL in humans. Gadobutrol is an inert contrast agent, without allergic reactions in animals

and with double density in comparison with other contrast agents. Gadobutrol has already been used in clinical studies as an intravenous agent for the imaging of brain tumors and of the central nervous system circulation (at a dose of 0.3 mmol/kg), and we preliminarily administered it subcutaneously

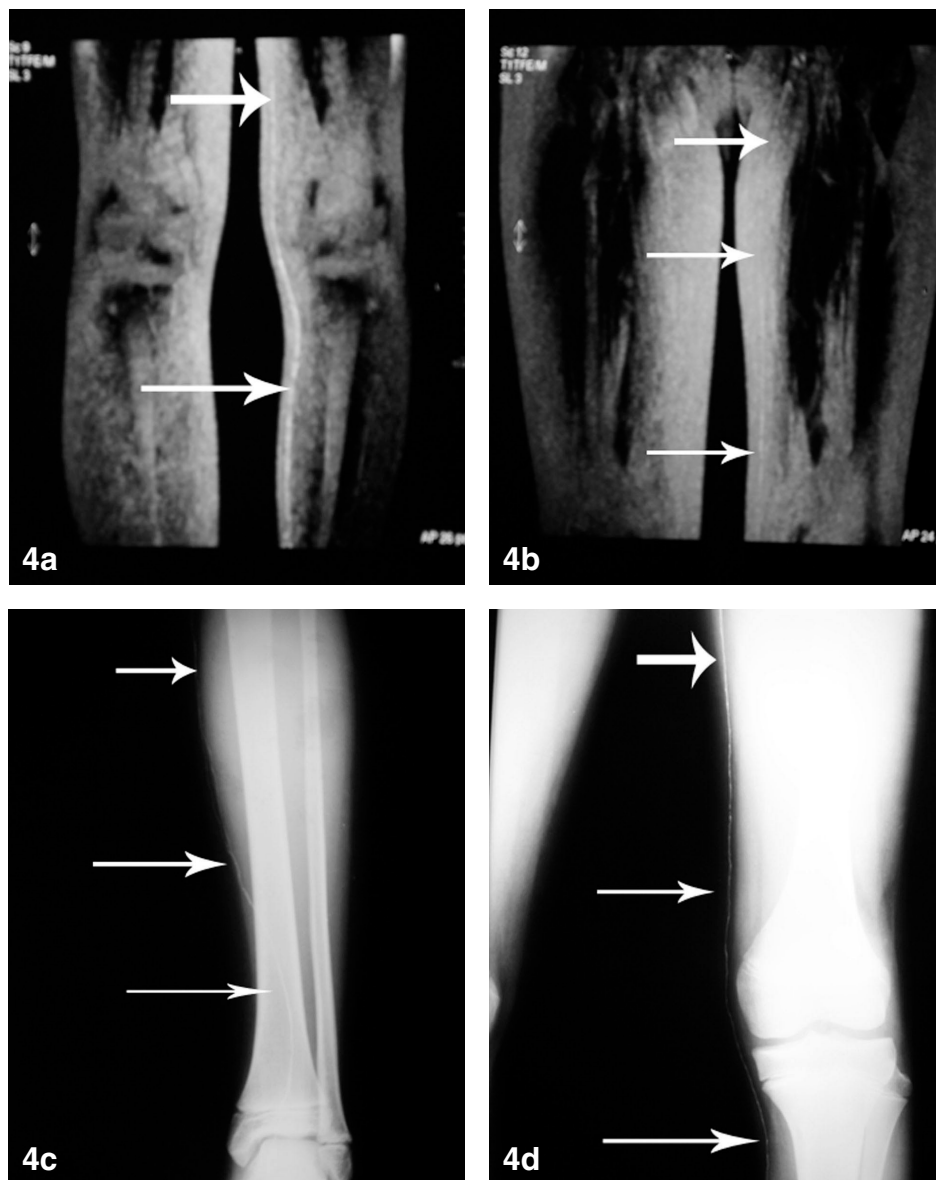


Fig 4. Depiction of a single lymphatic vessel (white arrows) in IMPRL (a,b) which was confirmed by direct x-ray lymphography (c,d) in a subject with lymphedema (No 10. from Table 1).

(20). In patients at various stages of lymphedema, we proceeded carefully to infuse Gadobutrol at a dose of only 0.06 mmol/kg (for one lower extremity) or 0.13mmol per kilogram of body weight (for both lower extremities). These doses are very low and pose no danger for the health of patients. The

technique of administration proved to be easy, and we were able to infuse a small amount of contrast agent (1.0 ml) in the subcutaneous space of the skinfold between the toes. Experiments in animals have demonstrated that massage of the injection site was necessary for optimal enhancement

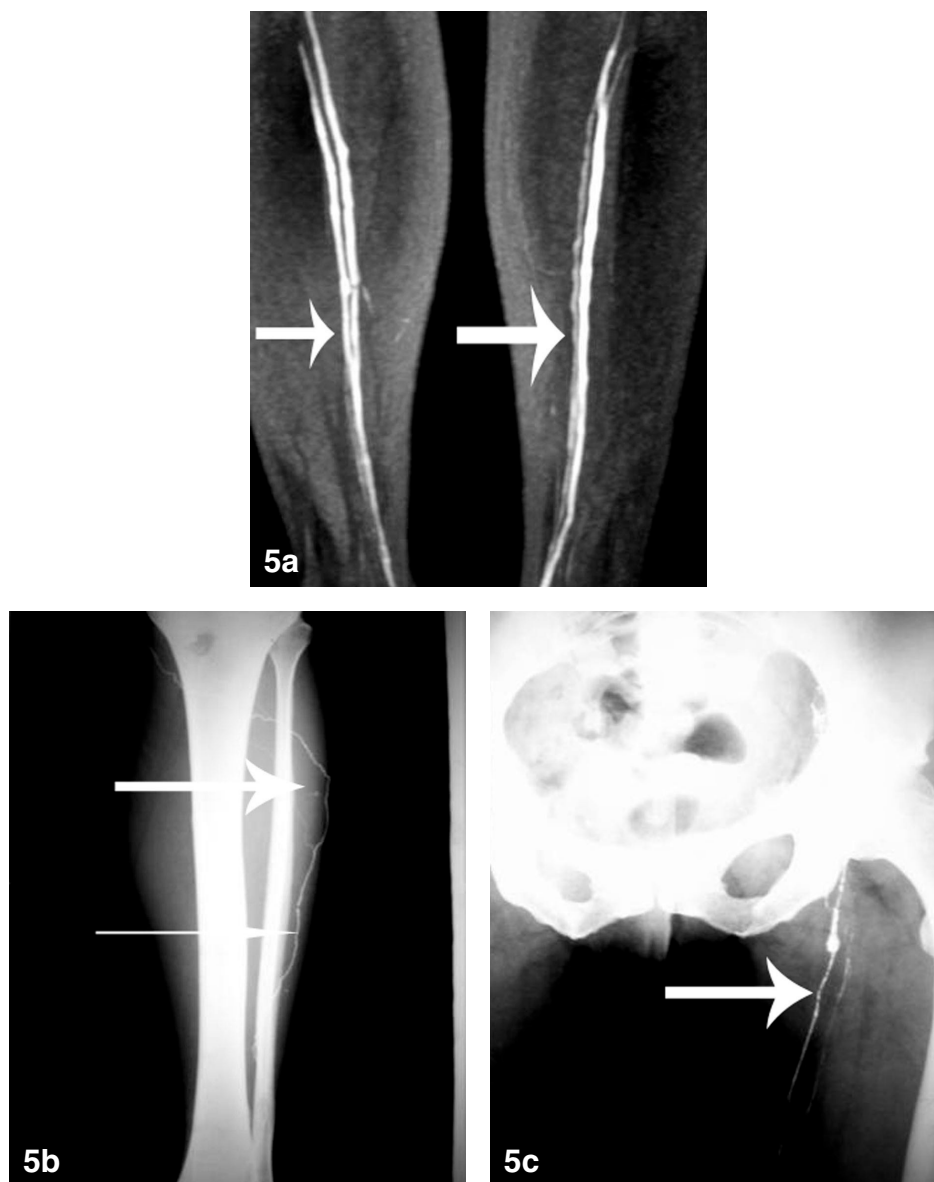


Fig 5. Depiction only of veins (a, white arrows) in IMPRL which was confirmed by direct x-ray lymphography (b,c) in a subject with lymphedema (No 7. from Table 1).

of the lymphatic system (20,22). We therefore massaged the injection site for about five minutes immediately after administration of gadobutrol for optimal imaging. The technique of subcutaneous administration of gadobutrol for MRL is simple and easy to perform in contrast to lipiodol administration for direct x-ray lymphography which entails

incision on dorsal foot to expose a peripheral lymphatic vessel and placement of a cannula to infuse the agent. This technique is stressful for the patient and can present serious technical difficulties especially in cases of severe lymphatic disease (peripheral lymphedema). In addition the wound must be protected from infections using antibiotics for 5-7 days.

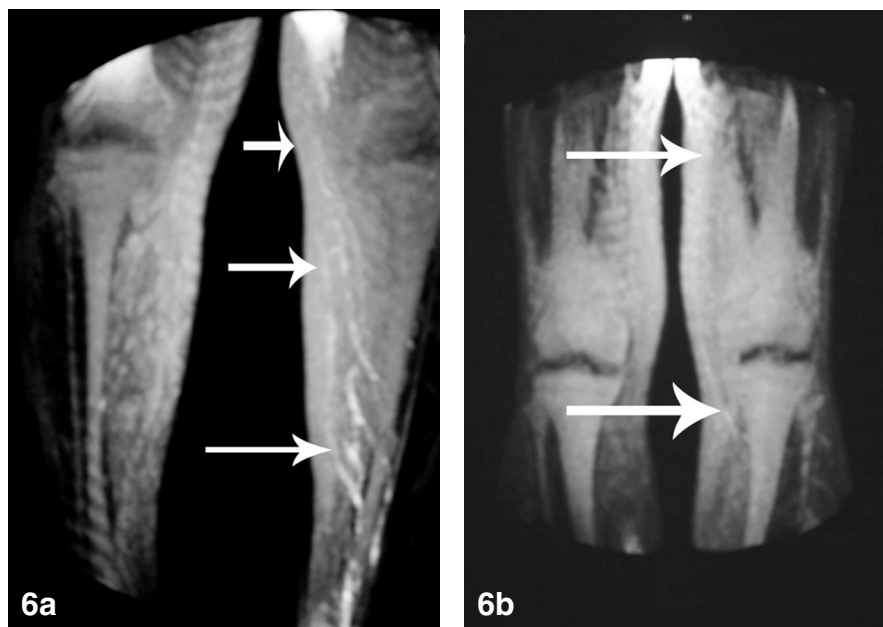


Fig 6. a,b) Depiction of a decreased number of lymph vessels (white arrows) by IMRL imaging (No. 12 from Table 1).

Depiction of the lymphatic system of the lower limbs with gadobutrol required approximately 60 minutes in volunteers and 60-90 minutes in subjects with lymphedema. We depicted the normal lymph vessels and inguinal lymph nodes in healthy controls and abnormal numbers (and presentation) of lymph vessels, presence of lymphoceles, and lack of inguinal lymph node imaging in subjects with lymphedema. The depiction of the lymphatic system with direct x-ray lymphography was seen in approximately 35 minutes after the administration and confirmed the findings of MR lymphography.

In MR lymphography, the urinary bladder was evident 5 minutes after the administration, which confirms a considerable degree of blood capillary absorption of the agent at the injection site or a rapid flow of the contrast agent from the lymphatic vessels into the venous system. The exact mechanism of gadobutrol uptake into the lymphatic system remains unknown (23,24). In 3 of 14 subjects, we depicted the lymphatic system simultaneously with the venous system. Moreover in two patients we succeeded to

only depict the venous system. We believe that this was due to a decreased number of the lymph vessels in the lower extremity and not in an unsuccessful imaging effort [one of the female subjects (No. 7) confirms our hypothesis – Fig. 5].

The use of gadobutrol as a contrast agent in MR lymphography is effective and can give us important details for the diagnosis of lymphatic disorders. In our study we administered very small dosages of gadobutrol and we may expect that our results will improve after determination of more accurate dosing of gadobutrol for MR lymphography. With further studies, we expect interstitial MR lymphography to evolve into a valuable diagnostic tool for the evaluation of lymphatic diseases primarily in the lower limbs and second, in regions other than extremities.

ACKNOWLEDGMENT

The authors thank Toumpis Serafeim and Krousaniotaki Kiriaki for their invaluable comments on the manuscript.

REFERENCES

1. Foeldi, M, E Foeldi, S Kubik: *Text book of Lymphology*. Urban and Fischer, Munchen, 2003, p. 253-254.
2. Kinmonth, JB: Lymphangiography in man. *Clin. Sc.*(1952), 11:13.
3. Witte, CL, WH Williams, MH Witte: Lymphatic imaging. *Lymphology* 26 (1993), 109-111.
4. Rudnick, MR, S Goldfarb, L Wexler, et al. Nephrotoxicity of ionic and nonionic contrast media in 1196 patients: A randomized trial. The Iohexol Cooperative Study. *Kidney Int.* 47 (1995), 254-261.
5. International Society of Lymphology: The diagnosis and treatment of peripheral lymphedema. Consensus document of the International Society of Lymphology. *Lymphology*. 36 (2003), 84-91.
6. Foeldi, M, E Foeldi, S Kubik: *Textbook of Lymphology*. Urban and Fischer, Munchen, 2003, p. 448-452.
7. Anzai, Y, KE Blackwell, SL Hirschowitz et al: Initial clinical experience with dextran-coated superparamagnetic iron oxide for detection of lymph node metastases in patients with head and neck cancer. *Radiology* 192 (1994), 709-715.
8. Wagner, S, D Pfefferer, W Ebert, et al: Intravenous MR lymphography with superparamagnetic iron oxide particles: Experimental studies in rats and rabbits. *Eur. Radiol.* 5 (1995), 640-646.
9. Bengele, HH, S Palmacci, J Rogers, et al: Biodistribution of an ultrasmall superparamagnetic iron oxide colloid, BMS 180549, by different routes of administration. *Magn. Reson. Imaging* 12 (1994), 433-442.
10. Fobbe, F, F Wacker, S Wagner: Arterial angiography in high-kilovoltage technique with gadolinium as the contrast agent: First clinical experience. *Eur. Radiol.* 6 (1996), 224-229.
11. Misselwitz, B, J Platzek, B Raduchel, et al: Gadofluorine 8: Initial experience with a new contrast medium for interstitial MR lymphography. *MAGMA* 8 (1999), 190-195.
12. Ruehm, SG, T Schroeder, JF Depatin: Interstitial MR lymphography with Gadoterate Meglumine: Initial experience in humans. *Radiology* 220 (2001), 816-821.
13. Kinno, Y, K Odagiri, K Andoh. et al: Gadopentetate dimeglumine as an alternative contrast material for use in angiography. *Am J. Roentgenol.* 160 (1993), 1293-1294.
14. Lohrmann, C, E Foeldi, O Speck, et al: High resolution MR lymphangiography in patients with primary and secondary lymphedema. *Am J. Roentgenol.* 187 (2006), 556-561.
15. Staks, T, G Schuhmann-Giampieri, T Frenzel, et al. Pharmacokinetics, dose proportionality, and tolerability of gadobutrol after single intravenous injection in healthy volunteers. *Invest. Radiol.* 29 (1994), 709 -715.
16. Vogler, H, J Platzek, G Schuhmann-Giampieri, et al: Preclinical evaluation of gadobutrol: A new extracellular contrast agent for magnetic resonance imaging. *Eur. Radiology* 21 (1995), 1-10.
17. Prince, MR, C Arnoldus, JK Frisoli: Nephrotoxicity of high-dose gadolinium compared with iodinated contrast. *J. Magn. Reson. Imaging* 6 (1996), 162-166.
18. Tombach, P, C Bremer, P Reimer, et al: Pharmacokinetics of 1M gadobutrol in patients with chronic renal failure. *Invest. Radiol.* 35 (2000), 35-40.
19. Fink, C, M Bock, F Kiessling, et al: Interstitial magnetic resonance lymphography with gadobutrol in rats: Evaluation of contrast kinetics. *Invest. Radiol.* 37 (2002), 656-662.
20. Dimakakos, E, A Koureas, V Skiadas, et al: Interstitial magnetic resonance lymphography with gadobutrol in rabbits and an initial experience in humans. *Lymphology* 39 (2006), 164-170.
21. Foeldi, M, E Foeldi, S Kubik: *Text book of Lymphology*. Urban and Fischer, Munchen, 2003, p. 251-252.
22. Ruehm, SG, C Corot, JF Depatin: Interstitial MR Lymphography with a conventional extracellular gadolinium-based agent: Assessment in rabbits. *Radiology* 218 (2001), 664-669.
23. Misselwitz, B, A Sachse: Interstitial MR lymphography using Gd-carrying liposomes. *Acta Radiol. Suppl.* 412 (1997), 51-55.
24. Heverhagen, JT, A Graser, A Fahr, et al: Encapsulation of gadobutrol in AVE-based liposomal carriers for MR detectability. *Magn. Reson. Imaging* 22 (2004), 4 83-487.

**Evangelos P. Dimakakos, MD, PhD,
EFA/VM, MLD/CDT (P)
Vascular Unit of 2nd Surgical Clinic
Aretaieion University Hospital of
Athens, Greece
Tel: +302106140560
E-mail: edimakakos@yahoo.gr**