

## MAGNETIC RESONANCE IMAGING AS A NEW METHOD TO DIAGNOSE PROTEIN LOSING ENTEROPATHY

N.-F. Liu, Q. Lu, C.-G. Wang J.-G. Zhou

Departments of Plastic & Reconstructive Surgery (N-FL,J-GZ), Shanghai 9th People's Hospital, and Radiology (QL), Shanghai Ren Ji Hospital, Shanghai Jiao Tong University School of Medicine; Department of Radiology (C-GW), Shanghai Chang Zheng Hospital, Shanghai, Second Military Medical University, Shanghai, People's Republic of China

### ABSTRACT

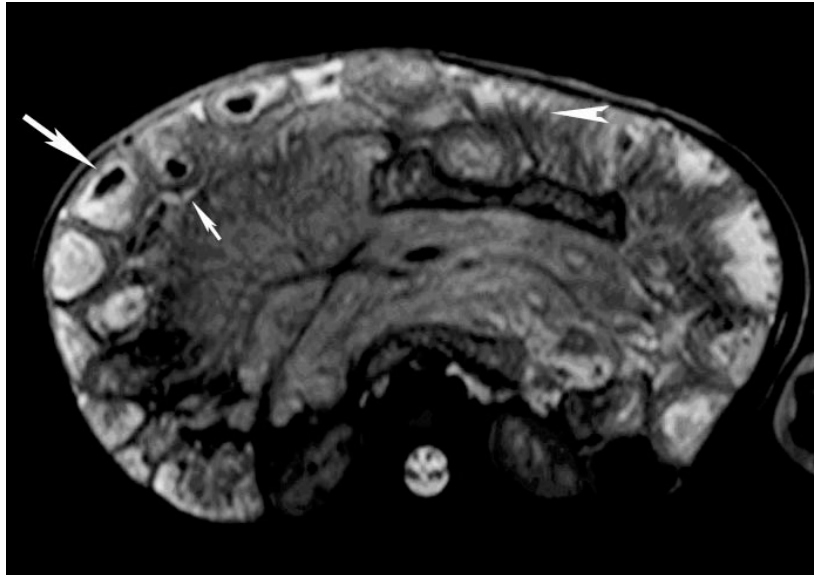
*The main cause of protein losing enteropathy (PLE) in children is intestinal lymphangiectasia. PLE is commonly diagnosed with radiotracer scintigraphy. We report the use of magnetic resonant imaging in diagnosis of a child with primary PLE. MRI clearly revealed abnormality in intestine and mesentery and dilated thoracic duct and mesenteric lymphatic as well as prominent subcutaneous lymphatics in the extremity. We conclude that MRI is a useful tool in diagnose of primary PLE.*

**Keywords:** magnetic resonance imaging, protein losing enteropathy, intestinal lymphangiectasia, children, lymphedema, mesentery, thoracic duct

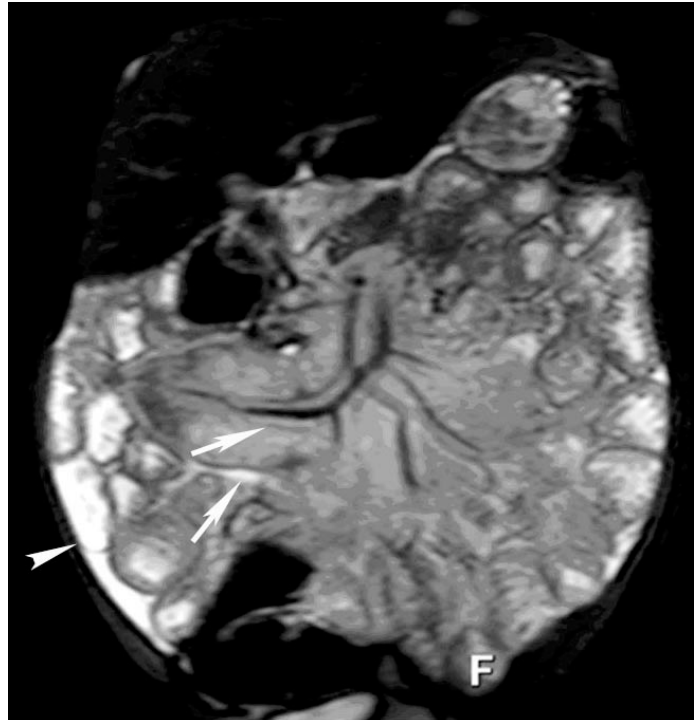
Protein-losing enteropathy (PLE) refers to a pathophysiologic condition that is characterized by the loss of serum proteins into the gastrointestinal (GI) tract. It may a primary manifestation or a secondary component of other diseases. One particular PLE called lymphostatic enteropathy is induced by intestinal protein leakage due to mechanical insufficiency of the lymph vessels and thus is characterized by lymphedema inside intestinal walls (1). In children, PLE is mainly a secondary component of intestinal

lymphangiectasia (2). The pathogenesis of primary PLE is largely unknown except that a systemic maldevelopment of the lymphatic system is generally considered as a main cause because the lymphatic disturbances exist in multiple organs and regions of the body. Clinical manifestations of primary PLE include one or more of the following: diarrhea, hypoalbuminaemia, hypoproteinemia, or anemia.

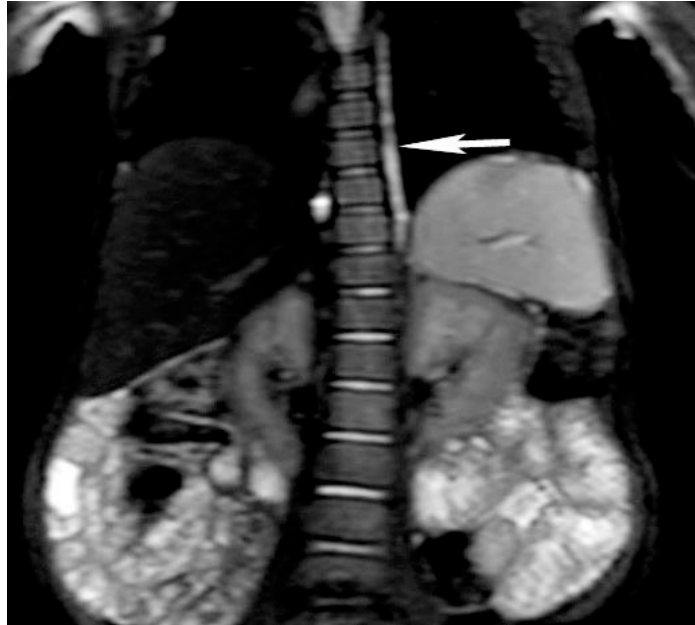PLE is traditionally diagnosed by a method using intravenously administrated isotopic macromolecules such as Technetium 99m-labeled macromolecules and then scintigraphy to detect loss of radionuclide inside intestinal lumen (3-5). However, first, Tc-99m macromolecules may not be sensitive enough for PLE diagnosis because the leakage of macromolecules is detected through the imaging in about 30% patients (6). Second, abdominal scintigraphy using intravenously injection of tracer is an indirect measurement. Intestinal biopsy is often required to provide further pathological evidences. Third, radionuclear scanning is time consuming (ranging from 0.5-24 hours). Finally, although wireless capsule endoscopy (7) may provide real-time imaging of small bowel in diagnosing PLE, it does not preclude the necessity to perform the biopsy for pathological examination. There is also the inherent disadvantage that it is difficult for



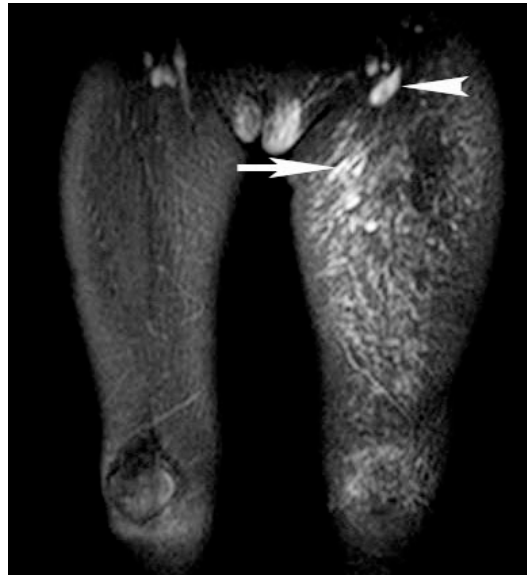*Fig. 1: Axial T2-weighted single-shot turbo spin echo (half-Fourier TSE) with fat suppression MR image revealed a diffuse mesenteric edema. Intramural hyperintensity in the jejunal wall (arrow) and diffuse thickening of the small bowel wall with submucosal fluid collections and a subserosal fluid ring surrounding small bowel loops (small arrow) were also detected. A so-called “comb sign” which represents edematous mucous membrane of ileum wall (arrow head) was observed.*



*Fig. 2: Coronal T2-weighted MR imaging displayed dilated mesenteric lymphatic (arrows) and ascites (arrow head).*



*Fig. 3: Coronal T2-weighted images of an extremely dilatated thoracic duct (arrow) with a diameter of 5 mm.*



*Fig. 4: Coronal T2-weighted image revealed prominent subcutaneous lymphatics (arrow) in the left lower extremity and enlargement of inguinal lymph nodes (arrowhead).*

children to swallow the wireless capsule. Therefore, a simpler and more efficient diagnostic tool remains to be identified.

Here we report a new method of diagnosis for PLE by performing a thorough

magnetic resonance scan on abdomen, thorax and extremities. The MR imaging revealed abnormality in the abdomen including intestinal swelling and mesenteric thickening. In addition, high resolution MR imaging

detected extremely dilated thoracic duct and mesenteric lymphatics as well as prominent subcutaneous lymphatics of lower extremities. Our results show that MR can examine both deep and superficial lymphatic system and discover pathological abnormalities in both viscera and extremity simultaneously. Therefore, MR imaging is a simple and efficient tool for primary PLE diagnosis. To our knowledge, this is the first report suggesting the use of MR in diagnosis of PLE.

#### CASE PRESENTATION

A two year old girl presented with edema in the left lower extremity at birth, progressive abdominal distension since the age of one, a 6-month history of chronic diarrhea, and occasional abdominal pain. The diarrhea became more frequent after eating fatty food. Clinically, there was no generalized edema. The abdomen was grossly distended. The left lower extremity showed non-pitting lymphedema. Swelling was also found on the left inferior abdominal wall, labia majora and buttocks. Abdominal ultrasound detected a small amount of ascites and enlargement of lymph nodes.

#### Results of Blood Tests

The following positive results were obtained: total serum protein 47 (68-81) g/L, albumin 25 (34-50) g/L, globulin 22 (23-25) g/L, serum alkaline phosphatase 145 (50-136) IU/L, prealbumin 0.20 (0.25-0.4) g/L, cholic acid 12.2 (0-10)  $\mu$ mol, serum protein electrophoresis  $\alpha_2$  14.4 (4.9-11.2%), serum protein electrophoresis  $\gamma$  9.0 (9.8-18.2%). Hemoglobin 109 (113-151), hematocrit 0.332 (0.335-0.45), MCV 66.0 (82.6-99.1), MCH 21.5 (26.9-33.3), red cell corpuscular volume 16.9% (11-15%), platelet count 522 (107-320), mean platelet volume 6.2 (8-12.5).

#### MR Imaging

The abdominal MR image revealed

marked mesenteric edema with swelling and thickening of small bowel wall (*Fig. 1*). The dilated mesenteric lymphatics were clearly visualized (*Fig. 2*). The abnormalities revealed by MR imaging were found mainly in the small intestine although there were also signs of edema in the colon. MR imaging of the chest showed an extremely dilated thoracic duct with a diameter of 5 mm (*Fig. 3*). MR imaging also revealed prominent subcutaneous lymphatics in the left lower extremity and enlargement of inguinal lymph nodes (*Fig. 4*).

Thus, the child was diagnosed with protein-losing enteropathy with hypoalbuminemia, hypoproteinemia, anemia and lower extremity lymphedema. For correcting the nutritional status and treatment, the child was started on a high protein and fat restricted diet supplemented with medium chain triglycerides and lipid soluble vitamins. One month later the symptoms of diarrhea and abdominal pain gradually disappeared.

#### DISCUSSION

We have been using MR imaging to diagnose lymphatic circulatory disorders in our clinic since 1996 (8). Magnetic resonance imaging exhibits superb resolution and multiplanar capability, which are critical in evaluating lymphatic malformations such as lymphangiectasia. T2-weighted 3 dimensional images are able to distinguish dilated lymphatics from the normal lymphatics (9). Moreover, MR imaging can extensively show superficial lymphatics in the subcutaneous, and deep lymphatic system in the thorax, and retroperitoneum as thoracic duct and lumbar lymphatic trunks (9). Such extensive examination is able to cover the full body abnormalities of the lymphatic system. In this study, MR imaging clearly detected a dilated thoracic duct and mesenteric lymphatic as well as prominent subcutaneous lymphatics of the lower leg. It also clearly revealed prominent pathological abnormalities such as the thickening of intestinal walls and

mesentery. Thus, MR imaging could provide indirect pathological evidence of intestinal and mesenteric abnormalities as well as malformations of both the central and peripheral lymphatic system. Additionally, the strong circumstantial evidence such as the history of chronic diarrhea, presence of ascites, abdominal distension, hypoproteinemia and hypoalbuminaemia were further evidence supporting a diagnosis of intestinal lymphangiectasia even without biopsy.

In conclusion, MR imaging is a non-invasive, rapid, safe and convenient method to examine lymphatic malformations and related pathological changes including those of primary PLE.

#### REFERENCES

1. Foldi E, Foldi M: Lymphostatic diseases. In: *Textbook of Lymphology*. M Foldi, E Foldi, S Kubik (Eds.), Munchen Urban & Fischer 2003, pp 305-310.
2. Waldmann, TA, JL Steinfeld, JF Duchter, et al: The role of the gastrointestinal system in "idiopathic hypoproteinemia". *Gastroenterol.* 41 (1961), 197-207.
3. Bhatnagar, A, R Kashyap, UPS Chauhan, et al: Diagnosing protein losing enteropathy a new approach using Tc-99m human immunoglobulin. *Clin. Nucl. Med.* 20 (1995), 969-972.
4. Shield, E, T Tucker, W Meyers, et al: Visualization of protein losing enteropathy in infantile systemic hyalinosis with Tc-99m HSA after albumin challenge. *Clin. Nucl. Med.* 21 (1996). 415-416.
5. Bhatnagar, A, D Lahoti, AK Sincy, et al: Scintigraphic diagnosis of protein losing enteropathy using Tc-99m dextran. *Clin. Nucl. Med.* 20 (1995), 1070-1073.
6. Oomen, R, G Kurien, N Balakrishnan: Tc-99m scintigraphy in the localization of protein loss in the gut. *Clin. Nucl. Med.* 17 (1992), 787.
7. Antao, B, J Bishop, R Shawis, et al: Clinical application and diagnostic yield of wireless capsule endoscopy in Children. *J. Laparosc. Adv. Surg. Tech.* 17 (2007), 364-370.
8. Liu, NF, CG Wang: The role of magnetic resonance imaging in diagnosis of peripheral lymphatic disorders. *Lymphology* 31 (1998), 119-127.
9. Liu, NF, CG Wang, MH Sun: Noncontrast three-dimensional magnetic resonance imaging vs lymphoscintigraphy in the evaluation of lymph circulation disorders: A comparative study. *J. Vasc. Surg.* 41 (2005), 69-75.

**Ning-fei Liu MD**  
**Department of Plastic &**  
**Reconstructive Surgery**  
**Shanghai 9th People's Hospital**  
**Shanghai Jiao Tong University**  
**School of Medicine**  
**639 Zhi Zao Ju Road**  
**Shanghai 200011, P.R.China**  
**Tel: 0086-21-63138341X5734**  
**Fax: 0086-21-53048025**  
**E-mail: liun2002**