

## LYMPH NODO-VENOUS SHUNT IN THE TREATMENT OF PROTEIN LOSING ENTEROPATHY AND LYMPHEDEMA OF LEG AND SCROTUM

S. Jamal

Consultant (Retired), Surya Medical Centre, Department of Plastic Surgery, Medical College, Thanjavur, India

### ABSTRACT

*Protein Losing Enteropathy (PLE) is a syndrome associated with several diseases affecting the gastrointestinal system. Recent comprehensive reviews can be found in eMedicine (1,2) and Gastroenterology (3). Treatment by surgery, lympho-venous anastomosis, excision of lymphangiectatic small bowel and gastrectomy and transplantation of the small intestine, depending upon the cause, have all been reported. We obtained a successful result for PLE associated with peripheral lymphedema by combining several sequential operative approaches including lymph nodo- venous shunt in the groin and reduction surgery for edema of the left leg and scrotum.*

**Keywords:** protein losing enteropathy, lymph nodo-venous shunt, lymphedema, debulking, chylous reflux, intestinal lymphangiectasis

### CASE REPORT

A young man of 21 years presented in 1998 with progressive leg and scrotal swelling despite custom-made support and treatment in several hospitals (Figs.1,2). His parents related a history of swelling of the left leg since birth, and diarrhea with recurrent attacks of fever and swelling of the scrotum for the past 10 years. There was no family history of lymphedema. A lower extremity

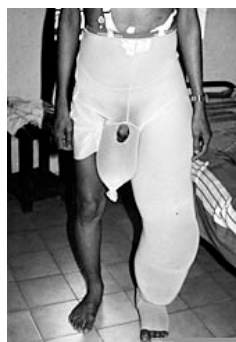

Fig. 1. Preoperative photograph with custom support (1998).

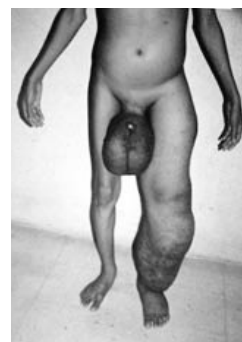
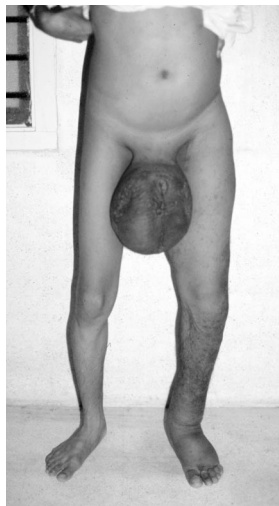
Fig. 2. Same as Fig. 1, without custom support (1998).

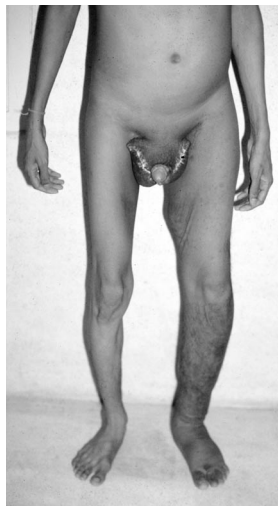lymphangioscintigram showed normal transport on the right side and no transport on the left from the foot injection site. Blood was negative for microfilaria. He was diagnosed with PLE from lymphangiectasia after intestinal biopsy showed intestinal lymphangiectasia and was instructed to avoid long chain triglycerides and use a medium chain triglyceride diet with added proteins. His diarrhea subsequently improved.

On admission to our hospital, laboratory tests revealed a very low serum albumin (1.1 gm%), total protein (2.9 gm%), and hemoglobin (6 gm%).

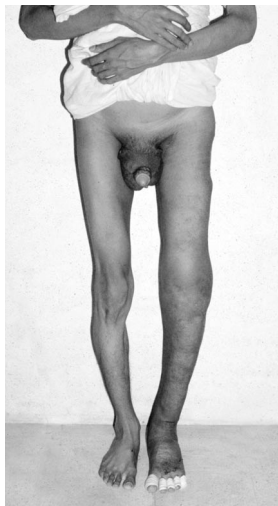
Based on our experience with performing more than 3000 nodo- venous shunts in the groin for lymphedema of the legs without mortality (4), nodo-venous shunt in the groin of the edematous left leg was carried out



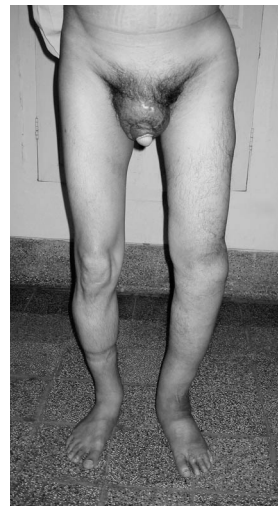*Fig. 3. Post left nodo-venous shunt with 50% reduction in leg edema (1998).*



*Fig. 4. Post-scrotal excision and sac excision and eversion (1999).*



*Fig. 5: Three years after nodo-venous shunt and thigh and leg reduction (2001).*



*Fig. 6: Eight years after operation (2006).*

under local anesthesia. Within 7 days, there was 50% reduction in the edema (*Fig. 3*). He left for college and came back after a year for operative reduction of the scrotal swelling. Excision and debulking of the scrotum was performed (*Fig. 4*). Two years later in 2001, he underwent left thigh and leg debulking (*Fig. 5*). In 2003, a right inguinal hernia repair was carried out along with a right nodo-venous shunt. The hernia sac contained a small amount of chylous fluid. He was last seen in 2006 at age 29 (*Fig. 6*). The plasma protein (6.2 gm%), albumin (3 gm%) and hemoglobin (12 gm%) were near normal. He was able to apply bandages very effectively in 1-2 minutes and control the swelling of the leg and is employed as a computer engineer. Lymphoscintigraphy was not available in our region to follow changes in lymphatic vessel and transport patterns after the series of treatments.

In our clinic, nodo-venous shunt has been performed usually in cases of lymphatic filariasis, intractable chyluria, chylous reflux into the scrotum and leg, and in cases of non-chylous lymph reflux into legs with very good results. This procedure can be tried in PLE

wherever there is lymphatic obstruction as, for example, from persistent central venous hypertension following the Fontan operation for congenital cardiac defects.

#### REFERENCES

1. Wright, R: Protein losing enteropathy. eMedicine. July 18,2005.
2. Wershil, BK: Protein losing enteropathy. eMedicine. Oct 24, 2002.
3. Landzberg, BR, M Pochapin: Protein-losing enteropathy and gastropathy. *Curr. Treatment Options Gastroenterol.* 4:39-49, 2001.
4. Jamal, S: Lymph nodo-venous shunt in the treatment of filarial elephantiasis. In: *Progress in Lymphology-VII*. Weissledder, H, V Bartos, L Clodius, (Eds.), Avicenum, Czechoslovak Medical Press Prague, 1981, 250-251.
5. Jamal, S: Lymphatic filariasis and the ISL Consensus Document. *Lymphology* 38 (2005), 193-196.

**S. Jamal, MD**  
**30-B Rajappa Nagar**  
**Thanjavur 613 007, INDIA**  
**Telephone #: 91 4362 234877; 320877**  
**FAX #: 91 4362 30355; 230637**  
**e-mail: dr.jamal@yahoo.com**