

## DISARTICULATION OF THE LEFT UPPER EXTREMITY FOR TREATMENT OF GIANT PRIMARY LYMPHEDEMA – CASE REPORT

M.F.P. Fraga, A.H. Júnior, H.J. Guedes Neto

Medical Resident of Plastic Surgery (MFPF); Master in Plastic Surgery of Santa Casa São Paulo, Faculty of Medical Sciences, and Chief of the Plastic Surgery (AHJ), Discipline of Irmandade da Santa Casa de Misericórdia; Medical Doctor (HJGN), Discipline of Vascular Surgery, Chief of Lymphology Unit, of Santa Casa de São Paulo, Faculty of Medical Sciences, São Paulo, Brazil

### ABSTRACT

*This unusually rare case of giant primary lymphedema of the left upper extremity in a 21-year old woman, who had undergone five surgical procedures (two Charles' procedures and three partial resections) without lasting clinical improvement, demonstrates the difficulty in achieving satisfactory long-term results in patients with grotesquely huge extremities secondary to primary lymphedema. Disarticulation of the left upper extremity was felt to be the most appropriate surgical option in this severe congenital lymphedema patient.*

### CASE STUDY

A 21-year old female with primary lymphedema involving the left upper extremity (Fig. 1A, B, and C) since age six and associated left humerus and thoracic cage abnormalities (Fig. 1D, E) was initially treated for five years with complex physiotherapy without clinical improvement. She was hospitalized on numerous occasions, approximately 15 times, for recurrent local infections (necrotic erysipelas) and two episodes of life-threatening systemic sepsis over the last two years.

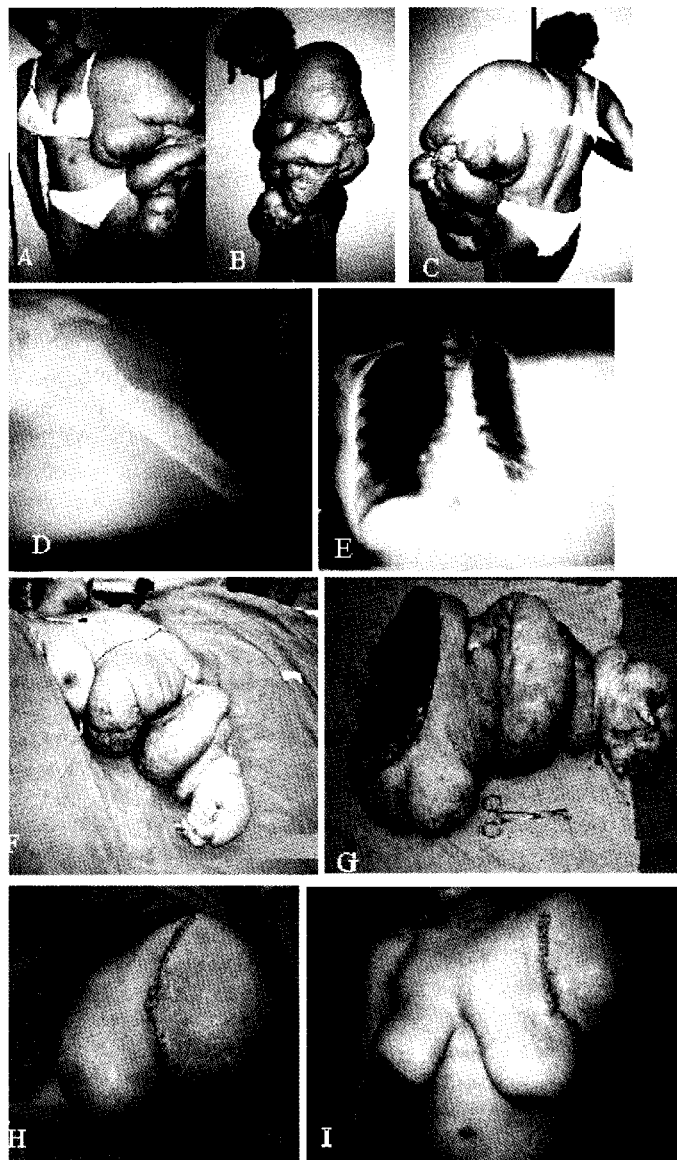
She underwent five surgical procedures (two Charles' and three debulking procedures)

over six years from 1998-2004. However, the patient's severe left upper extremity deformity persisted with a diameter of the left arm 5 cm greater than her torso. She presented at this time with recurrent episodes of local infections, ulcerations, deformity of the thoracic cage (Fig. 1E), and the inability to undertake activities of daily living. Thus, the decision was made to proceed with disarticulation of the extremity as the treatment of choice (Fig. 1F,G,H, and I).

Lymphoscintigraphy revealed paucity of lymphatic collectors and dermal backflow in the left forearm and arm.

### DISCUSSION

The difficulty of treating severe primary and secondary lymphedemas has challenged physicians for generations. Patients with these disorders require a multidisciplinary therapeutic approach involving psychologists, physiotherapists, and surgeons. According to Morgan et al (1), the initial treatment showing an 80% success rate involves complex physiotherapy in patients predominantly with less severe lymphedema. This is a non-invasive treatment which does not require medications or subject the patient to significant risks. Surgical intervention is generally reserved for the group of individuals who do not respond



*Fig.1. Congenital lymphedema of the left upper extremity. A,B,C show the enormity of the left upper extremity, even after five previous operative procedures. D,E demonstrate the skeletal deformities of the left humerus and thoracic cage radiographically. F,G,H show the planned disarticulation markings, the disarticulation specimen and the forequarter amputation site at the completion of the procedure. I shows the appearance of the surgical site 15 days post-operatively.*

to conservative measures, have significant functional limitations in activities of daily living, and/or present with severe cosmetic deformities.

Numerous operative techniques are described in the literature for treatment of

lymphedema, with disagreement existing as to which offers the best long-term results. These procedures can be classified as physiologic or resective. The physiological procedures include omental transposition, microsurgical anastomoses (lymphovenous,

lympholymphatic, lymph nodo-venous, and lympho-lymphatic interpositional or bypass grafts) and Thompson's procedure.

The resective procedures which debulk large quantities of skin and subcutaneous tissue have demonstrated more consistent long-term results, as demonstrated by Schnur et al (2). They presented 14 patients with lymphedema of the lower extremities who underwent debulking procedures. These patients demonstrated a reduction in the incidence of infections as well as in symptoms and an improvement in their quality of life at long-term follow-up. For reasons not yet well delineated, patients with lymphedema of the upper extremity present less satisfactory results with resective procedures as demonstrated by Guedes et al (3).

According to Miller et al (4), the Charles procedure, which consists of the complete excision of the subcutaneous tissue and placing a split thickness skin graft to reconstruct the defect, demonstrate poor results complicated by the loss of the skin grafts, chronic ulcerations and deforming scars.

Campisi et al (5) have used microsurgical procedures in the treatment of peripheral lymphedema with an average reduction in excess volume of 69% and a 87% reduction in the incidence of cellulitis. They have found improved results can be expected with procedures performed in the first stages of lymphedema. These procedures would most likely not be appropriate or effective in this patient.

Liposuction combined with controlled compression therapy has been shown to reduce arm lymphedema significantly more effectively than compression alone in patients after breast cancer therapy, with an average reduction in excess volume of 93% as demonstrated by Brorson et al (6). The presence of intense fibrosis and, in this case, immense swelling and our lack of experience in other surgical procedures for the treatment of giant primary lymphedema cases was a factor in why liposuction techniques were not used.

Amputation of a limb represents a radical measure and obviously a last resort because of the generally benign indolent nature of lymphedema disorders. Amputations are only indicated in the most severe and refractory cases where lesser treatment modalities have failed, such as in the case report presented. Perhaps the explosion of molecular understanding of lymphatic growth, including genetic insights, that has taken place in the past decade in combination with early detection and treatment will provide us with alternatives for prevention and control of the underlying lymphatic abnormalities in structure and function that culminate in this end-stage condition.

#### REFERENCES

1. Morgan, RG, JR Casley-Smith, MR Mason: Complex physical therapy for the lymphoedematous arm. *J. Hand Surg.(Br)* 17 (1992), 437-441.
2. Schnur, PL: Surgical treatment of lymphedema—A reappraisal. *Vasc. Surg.* 11 (1977), 182-187.
3. Guedes Neto, HJ: Resective Surgery. *Proceedings of the 16th International Congress of Lymphology, Madrid, 285-287, 1997*
4. Miller, TA, LE Wyatt, GH Rudkin: Staged skin and subcutaneous excision for lymphedema: a favorable report of long-term results. *Plast. Reconstr. Surg.* 102 (1998), 1486-1498.
5. Campisi, C, F Boccardo, A Zilli, et al: Lymphatic reconstructive microsurgery: over 25 years of clinical outcomes. *J Reconstr. Microsurg.* 19 ( 2003), 598-599.
6. Brorson, H, H Svensson: Liposuction combined with controlled compression therapy reduces arm lymphedema more effectively than controlled compressin therapy alone. *Plast. Reconstr. Surg.* 102 (1998), 1058-1067.

**Murillo F.P. Fraga, MD**  
**Av. Lineu de Paula Machado 738**  
**CEP:05601-000**  
**Cidade Jardim, São Paulo, Brasil.**  
**Tel: 55-11-38190190**  
**E-mail: murifraga@ig.com.br**