

AXILLARY LYMPH DRAINAGE AS A PROGNOSTIC FACTOR OF SURVIVAL IN BREAST CANCER

K. Kett, K. Szilágyi, B. Anga, A.G. Kett, K. Királyfalvi

Third Department of Surgery (KK,KS) and Central Research Laboratory (KK), University Medical School Pécs and Department of Pathology (BA), Baranya County Hospital Pécs, Hungary, and Department of Anesthesiology (AGK), NYU School of Medicine, New York City, USA

ABSTRACT

Axillary lymph node staging is an important prognostic factor in patients with breast cancer. The long-term survival is poor if the number of metastatic axillary lymph nodes exceeds three. With 1-3 metastatic lymph nodes, survival in 30% of the patients is 20 years. The markedly different outcome of these patients with metastatic axillary lymph nodes suggests that other factors likely play a critical role in breast cancer dissemination. In this study, we examined the association of impaired axillary lymph drainage with breast cancer survival. Fifty patients with breast cancer underwent direct breast lymphography before treatment to evaluate the status of ipsilateral axillary lymph nodes and lymph drainage at time of presentation. Twenty-five patients with signs of metastatic disease and/or impaired lymph drainage were followed for 10 years. Seven of 25 patients survived 10 years; 6 are tumor free; and 1 has distant metastases. The other 18 patients died during the 10 year period. Seventeen of the 18 died from disseminated breast cancer; 1 died of unrelated disease. In the survivors, direct breast lymphography showed normal breast lymph drainage. All patients with distant metastases had obstructed lymph vessels at the time of original diagnosis. These findings suggest that the chance for survival is determined both by the status of axillary

lymph drainage as well as the number of metastatic axillary lymph nodes.

Axillary lymph node staging, or the number of involved regional lymph nodes with metastasis, is to date the best prognostic indicator of survival from breast cancer. It also plays an important role in the selection of cytotoxic adjuvant therapy. Based on the observation that the chance for survival dramatically decreases when the number of axillary lymph-node metastases exceeds three, it has been suggested (1) that patients be stratified into two groups. Group 1 includes those with 1-3 regional metastases (N1-3) and Group 2 includes patients with four or more positive axillary lymph nodes (N>3). Even when the first group was divided into 3 further subgroups (2), no further survival rate advantage was identified. Although still not entirely clear, breast cancer patients with micrometastases have been regarded as having a prominently good prognosis (3-5). Many patients die with a single axillary lymph node metastasis, whereas others with three or even more positive regional lymph nodes with tumor survive tumor free for as long as 20 years (6). This disparity suggests other factor(s), which can not be fully correlated with the number of lymph nodes involved, to explain survival. We report an important link that changes in axillary lymph drainage in conjunction with

involvement of regional lymph nodes with metastases alter prognosis.

MATERIALS AND METHODS

By physical examination alone, the axillary nodal status for cancer has 30 % false results (7). In our patients, this rate was 28%. To improve assessment with axillary nodal status, we used direct breast lymphography (8). This technique was performed in 25 patients with breast cancer with histologically established axillary nodal metastasis. Fifteen patients had N1-3+, while 10 patients had N>3 + axillary lymph nodes. The mean age of the patients was 42 years (range 31 to 72 years). Preoperatively, the patients were screened for distant metastases using clinical tools including ultrasound, chest X-ray and bone scan. In each patient, a modified radical mastectomy was performed with dissection of levels I-II of the axillary lymph nodes. All tumors and lymph nodes were examined histologically (all tissue specimens were formalin-fixed, paraffin embedded and sections were stained with hematoxylin and eosin). All patients received cytotoxic chemotherapy and hormone therapy (Tamoxifen). The patients were followed up with chest X-ray, bone scintigraphy annually and liver ultrasound every 6 months for 10 years.

Direct Breast Lymphography

The procedure was performed 24 hours before operation according to a method published before (9). In brief, 0.5-1 ml of vital dye (Patent blue violet, Konstanz) was injected into the skin at the lower edge of the areola. From an incision made in the region of the upper outer quadrant of the breast a blue-dyed lymph vessel was dissected, cannulated with a 27 gauge needle and 2-3 ml of Lipiodol Ultra Fluid was injected. After the injection, a chest X-ray was taken, which was repeated after 24 hours. There were no complications with this method. Lymphograms were evaluated by a team of surgeons and radiologists.

RESULTS

Lymphography

Based on the lymphograms, the patients were classified into 3 groups (Table 1).

Group 1: In 7 of the 25 patients no sign of lymph drainage obstruction were seen on the lymphograms. Six of the 7 patients had N1-3 positive lymph nodes (1 positive lymph node was found in 2 patients, 2 were found in 2 other patients, and 3 were found in another 2 patients) and in 1 patient, 4 metastatic lymph nodes were found. The vital dye injected outlined a blue patch in the skin of the areola, from where one or two principal cutaneous lymph vessels ran towards the axilla in most patients. On the lipiodol lymphogram (Fig. 1), similar to the unaltered anatomy in the axilla-negative patients, the principal lymph vessel was seen as a thin thread running to the primary draining lymph nodes. Lymph nodes of levels I, II and III appeared with intact edges and structures.

Group 2: On the lymphograms of 6 patients, signs of lymph drainage obstruction were detected. All patients of group 2 had N1-3 positive lymph nodes (3 patients had 1, another 3 patients had 3 positive lymph nodes). The vital dye injected appeared as irregular blue patches with blurred edges suggesting dermal backflow. No principal cutaneous lymph vessel was seen on the skin. On a lipiodol lymphogram the principal lymph vessel ran off tortuous and dilated, and the primary draining lymph node filled incompletely (Fig 2 inset). At the injection site, a part of the contrast material flowed back along the needle.

Group 3: In 12 patients, chronic lymph stasis was encountered. The number of positive lymph nodes was 1 in 3 patients and N>3 in 9 patients. The violet dye injected into the skin of the areola accumulated consistently with various degrees of backflow. A principal cutaneous lymph vessel was rarely visualized. Injection of lipiodol into the cannulated lymph vessel was difficult as a large portion of the contrast flowed back

TABLE 1
Classification of Prognostic Factors (Tumor Size, Number of Positive Lymph Nodes, and Degree of Involvement) According to the Lymphographic Pattern

No.	N 1-3												N > 3				
	N 1				N 2				N 3				NN	T	NS	C	SR
	T	NS	C	SR	T	NS	C	SR	T	NS	C	LR					
Level I																	
1	3	22	—	LF													
2	5	7	—	LF													
3					1.5	10	—	LF									
4					2.5	9	—	D*F									
5									3	9	—	LF					
6									4	5	—	LF					
7													4	2.5	8	—	LF
Level II																	
8	2	7	—	DR													
9	3	6	—	DR													
10	3	10	—	DR													
11									2.5	8	—	DR					
12									5	7	—	DR					
13									5	10	—	LR					
Level III																	
14	3.5	6	—	DR													
15	4	3	—	DR													
16	6	8	—	DR													
17													4	1	8	—	DR
18													4	2	19	+	DR
19													4	8	9	—	DR
20													5	4	10	+	DR
21													6	1.5	14	—	DR
22													7	4	11	—	DR
23													8	3	7	—	DR
24													11	2.5	11	—	DR
25													12	10	10	—	DR

No=serial number of patients; T=tumor size (cm); NS=maximal tumor diameter in the positive lymph nodes; C=capsule infiltration (— no; + yes); SR=L = live; D = died [D*=died of unrelated causes]; R=tumor recurrence; F=free of tumor; NN=number of positive lymph nodes


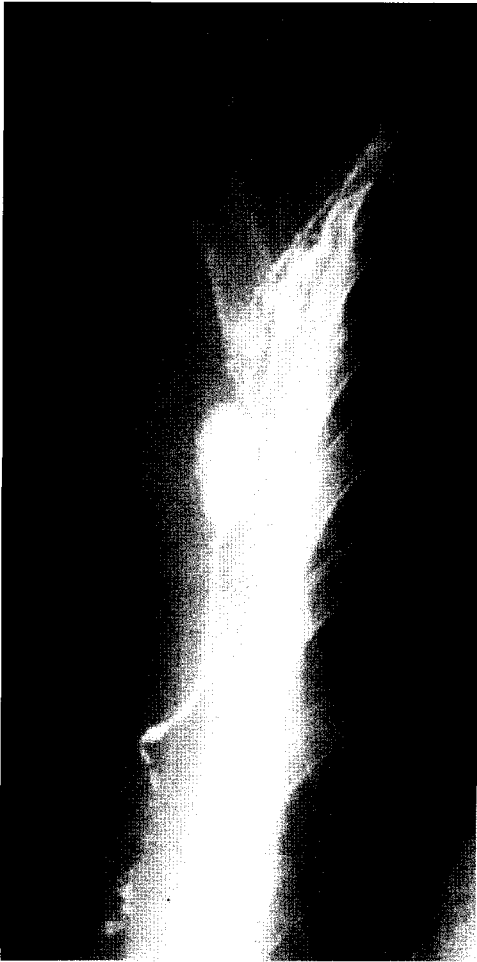


Fig 1. Breast lymphogram, Group I. Nodes negative. No impairment to lymph flow.

along the needle. Part of the draining lymph nodes showed irregular edges and structure. The internodal lymph vessels formed bypasses around positive lymph nodes (*Fig 3*).

The violet dye test was easily performed and the lymphogram properly analyzed in group 1. Inserting a cannula and injecting Lipiodol into a lymph vessel was difficult on several occasions in group 2 and 3 due to obstructed lymph flow induced by lymph nodal metastases. A portion of contrast material regurgitated due to increased resistance, and in order to obtain a proper image, the amount of Lipiodol had to be increased. Separation of groups 2 and 3 was

difficult as these groups represented a similar process with different degrees of severity, which made the phenomenon overlapping.

FOLLOW-UP

After 10 years, 7 of the 25 patients were alive, 6 free of tumor while 1 was living with distant metastases. Eighteen patients had died; 1 was tumor free who died from another disease 8 years later; the other 17 died from the recurrence of breast cancer (*Table 1*).

The Relationship Between Tumor Recurrence, Survival and the Number of Positive Lymph

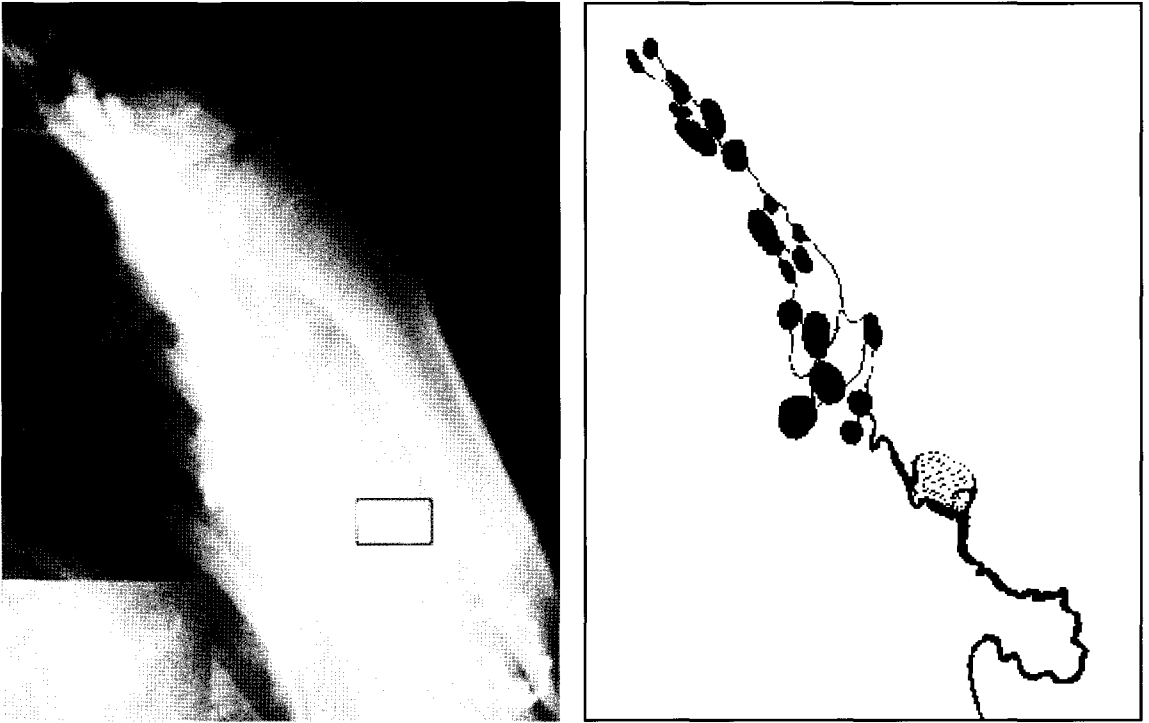


Fig 2. Breast lymphogram, Group II. Slightly impaired lymph drainage with poorly detected proximal lymph node (inset).

Nodes

Five of the 15 patients in the N1-3 group were tumor free after 10 years and another patient (the one who died from another disease after 8 years) was also tumor free. One patient survived with distant metastases for 10 years, 8 patients died from distant metastases within 7 years.

One of the 10 patients in the N>3 group was alive after 10 years and was tumor free. Nine patients died from disseminated carcinoma within 7 years.

The relationship between the 10-year tumor-free survival and the number of positive axillary lymph nodes was not significant (Fig. 4).

Recurrence and Survival in Respect to Breast Lymphography

Group 1: Six of the 7 patients showed no signs of lymphatic stasis and were alive and tumor free after 10 years. One patient died from an unrelated disease after 8 years. One patient had 4, the rest of them had 1-3 lymph node metastases.

Group 2: None of the 6 patients were tumor-free after 10 years. One was still alive with distant metastases, and 5 died within 7 years due to tumor distant metastases.

Group 3: None of the 12 patients was alive after 10 years. They all had died within 7 years from tumor dissemination.

Tumor-free survival data of lymphographic group 1 compared to those of groups 2 and 3 are shown in Fig 5.

Table 1 demonstrates the relation of tumor size and axillary lymph node staging to the status of axillary lymph drainage. There was no micrometastasis.




Fig 3. Breast lymphogram, Group III. Markedly impaired lymphatic drainage.

DISCUSSION

In this study the effects of the number of positive lymph nodes and the status of axillary lymph drainage were examined.

a) Using conventional criteria, patients with $N \leq 3$ and those with $N > 3$ positive lymph nodes were identified. To assess the prognostic value based on the number of positive axillary lymph nodes survival rates in the sample of 10 years after surgery were compared in the two groups. Using a log rank test the differences were not significant (tumor-free survival rate $P=0.07$).

b) To assess the prognostic value of direct breast lymphography, the survival

rates of group 1 were compared to those in groups 2 and 3. Based on lymphographic data, significant differences were found between the two groups ($P= 0.0000$). The data show that 6 patients with 1 positive lymph node died within 7 years after modified radical mastectomy, whereas 2 patients with 3 and 1 patient with 4 positive lymph nodes were alive and tumor-free after 10 years. Expected 10-year-survival rate of patients by age if they had not developed breast cancer were: group 1 (5.72/7[82%]); group 2 (5.29/6[88%]); group 3 (9.64/12[80%]). These data suggest that the prognostic value of positive axillary lymph nodes can be improved by including lymph vessel

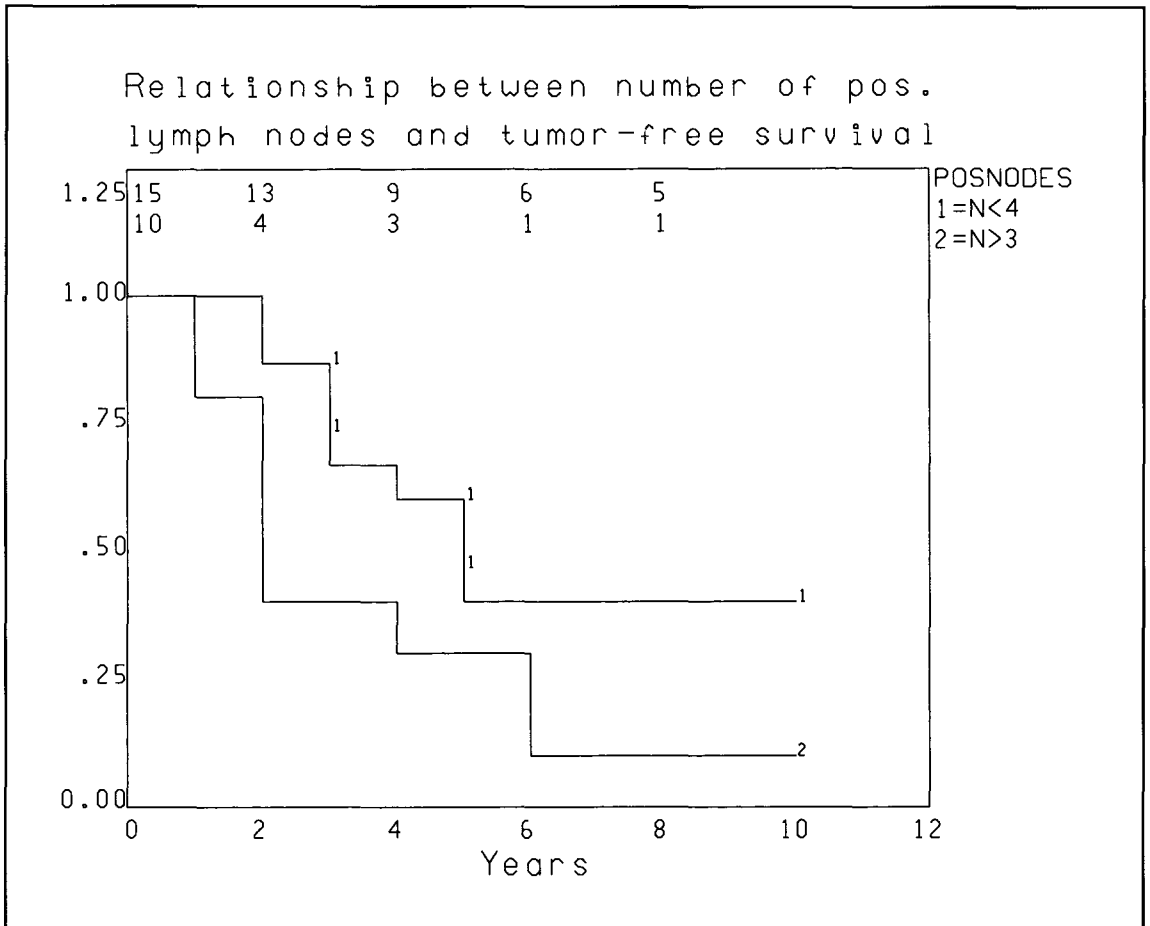


Fig 4. Tumor-free survival curves based on the number of positive axillary lymph nodes.

obstruction as a result of tumor involvement of the regional lymph nodes. Direct breast lymphography showed no sign of lymph node metastasis of 1 lymph node in 2 patients, 2 lymph nodes in 2 patients, 3 lymph nodes in two patients, and 4 lymph nodes in 1 patient. Signs of lymph stasis were not recognized, and these patients constitute the group of 10-year survivors. The importance of lymph stasis is also supported by the fact that 6 patients with 1, another 3 patients with 3 positive, and 9 patients with >3 lymph nodes (who each showed signs of lymph stasis), died during the follow-up period, excepting 1 patient with 3 lymph node metastases.

The contradiction between positive

histological findings of metastases in the lymph nodes and the "negative" lymphograms and the survival data can be explained by the relationship of the anatomical variation of the lymph nodes and their draining lymph vessels.

The communication between the plexus of lymph vessels in the areola of the breast was first described by Sappey (10). Grant et al (11) studied this communication further and specifically the role of the subareolar plexus in the lymphogenic dissemination of breast cancer. They suggested that the afferent lymph vessels of the parenchyma and the branches of the superficial dense plexus of the areola flow into the subareolar plexus

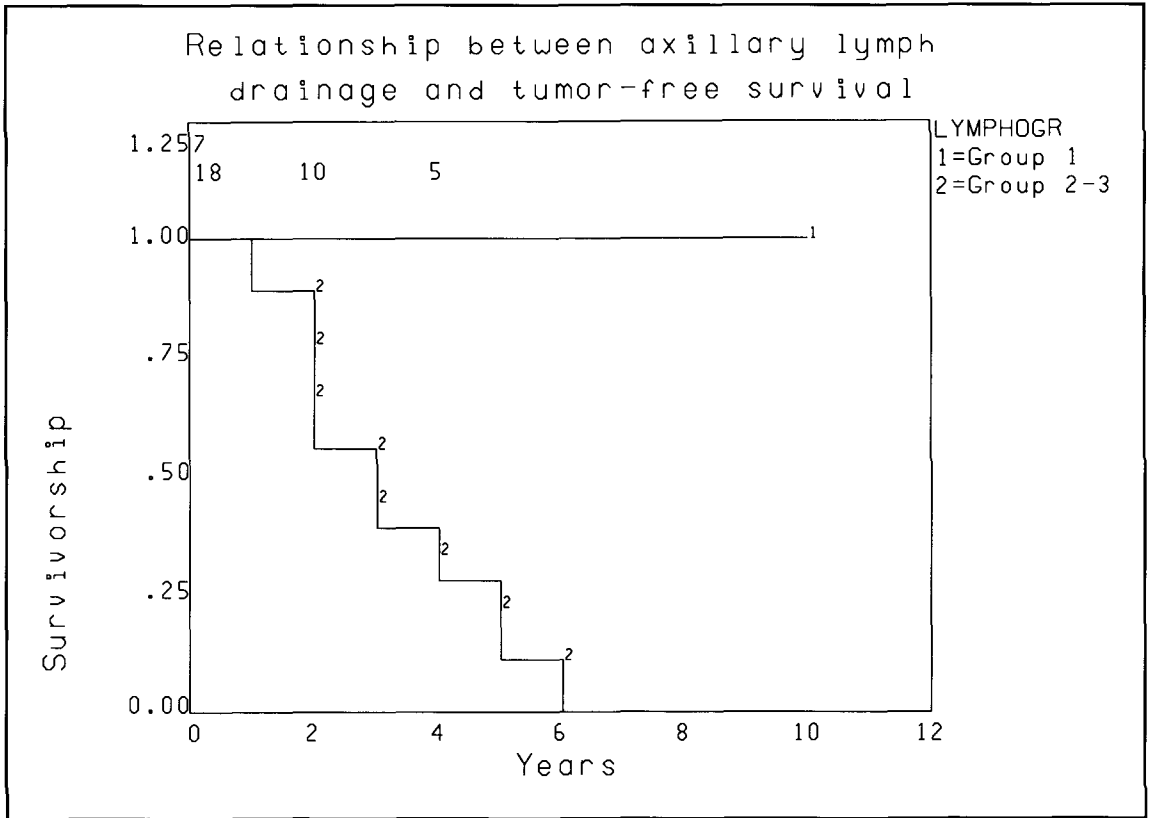


Fig 5. Tumor-free survivals based on the status of axillary lymph drainage.

from where lymph is drained through the principal axillary pathway into the axillary lymph nodes. From the skin covering the breast the lymph is collected by the periareolar plexus communicating with the parenchymal system and is drained through the principal cutaneous pathway uniting with the epifascial lymph vessel into the axillary lymph nodes. Whereas the communication between the plexus makes the lymph drainage of the breast uniform, the relationship of the lymph vessels and lymph nodes makes a number of anatomical variations possible. One common lymph node may drain all the lymph vessels but the lymph pathways of the parenchyma and the cutis may run separately to two or more lymph nodes. The two lymph pathways may run parallel along a short distance and they may join only after

passing a few interposed nodes (12), thereby consisting of a number of sentinel lymph nodes. In this situation, if tumor cells disseminate through one pathway and form metastases, the other cutaneous lymph pathway may provide uninterrupted lymph drainage. As lymphographic contrast material is injected into the cutaneous principal lymph vessel, the lymph nodes and lymph vessels involved in tumor formation may not uniformly be seen on the lymphograms. Lymph stasis does not occur as long as lymph freely drains from the breast parenchyma through the communication of the plexus and the cutaneous lymph pathways. We found that the prognosis of those patients with unimproved lymph drainage was similar to those with negative axillary lymph nodes.

Earlier, based on the findings of direct breast lymphography, the senior author (KK) highlighted the importance of altered lymph vessels associated with lymph node metastases (13). However, the advanced stage of these breast cancer patients made it impossible to assess long-term survival. The axillary lymph node staging of patients included in the present study is more favorable in this respect. In 15 of 25 axillary nodal positive patients, dissemination of the tumor did not spread further than the area of another 3 lymph nodes, and the distribution of metastases was balanced. Comparing the 10-year survival rates of patients in group N1-3 with those in group N>3 positive lymph nodes, we found unfavorable outlook in the latter group (similar to others). It was impossible, however, to identify prognostically homogeneous groups based solely on the number of positive lymph nodes.

The lymphogenic dissemination of breast tumor results not only in regional metastasis. Lymph stasis also occurs when the afferent lymph vessels becomes occluded. Disturbed lymph drainage, however, does not consistently result in nodal metastases. Using direct breast lymphography, impaired lymphatic axillary drainage was depicted in 3 of 5 patients only on the basis of a single lymph node metastasis. With N1-3 positive lymph nodes, signs suggesting lymph stasis were found in 9 of 15 patients, while in the situation of N>3 positive lymph nodes pathological lymph vessels were found in 9 of 10 patients. It was interesting to note that low numbers of lymph node metastases, mostly associated with the dilation of afferent lymph vessels, were accompanied by a network of collateral lymph vessels. In 7 patients, however, lymphography was at odds with the histological findings. Thus, by microscopy, lymph node metastases were detected but could not be seen on lymphography nor was their evidence of lymph stasis. Yet, knowledge of the status of the lymph drainage further provided a correlation between patient survival rate and the number of positive axillary lymph nodes.

These results suggest that the prognosis of patients with breast cancer is more reliably assessed if besides the classical criteria of tumor size, number and size of positive lymph nodes that the capacity of the lymphatic drainage be assessed. Where there is no sign of lymph stasis and N< 3 positive lymph nodes, the patient survival rate corresponds to that expected for age.

Direct lymphography is not easy to perform from a technical point of view. It is time consuming but without its application we would not have detected the prognostic value of impaired lymph drainage in conjunction with axillary node staging for metastasis. Perhaps a simpler technique such as lymphoscintigraphy can be semiquantified to detect impaired lymph drainage as well as assessment of lymph nodes to improve prognostication in patients with breast cancer.

REFERENCES

1. Fisher, B, RG Ravdin, RK Ausmann, et al: Cooperating investigators. Surgical adjuvant chemotherapy in cancer of the breast: Results of a decade of cooperative investigation. *Ann. Surg.* 168 (1968), 337-356.
2. Fisher, B, M Bauer, Lwickerham, et al: Relation of number of positive axillary nodes to the prognosis of patients with primary breast cancer. An NSABP update. *Cancer* 52 (1983), 1551-1557.
3. Huvos, AG, RVP Hutter, JW Berg: Significance of axillary macrometastases and micrometastases in mammary cancer. *Am. Surg.* 173 (1971), 44-46.
4. Attiyeh, F, M Jensen, AG Huvos, et al: Axillary micrometastasis and macrometastasis in carcinoma of the breast. *Surg. Gynecol. Obstet.* 144 (1977), 839-842.
5. Rosen, PP, PE Saigo, DW Braun, et al: Axillary micro and macrometastases in breast cancer. *Am. Surg.* 194 (1981), 585-591.
6. Gardner, B, J Feldman: Are positive axillary nodes in breast cancer markers for incurable disease? *Ann. Surg.* 218 (1993), 270-278.
7. Fisher, B, N Wolmark, M Bauer, et al: The accuracy of clinical nodal staging and of limited axillary dissection as a determinant of histologic nodal status in carcinoma of the breast. *Surg. Gynecol. Obst.* 152 (1981), 765-772.

8. Kett, K, L Lukács: Diagnosis of regional lymph node metastases in cancer of the breast. *Amer. J. Surg.* 128 (1974), 398-401.
9. Kett, K, G Varga, L Lukács: Direct lymphography of the breast. *Lymphology* 3 (1970), 3-12.
10. Sappey, PC: Anatomiephysiologie et pathologie des vaisseaux lymphatiques considérées chez l'Homme et les vertébrés. A Delahaye and E.Lecrosier, 1874.
11. Grant, RN, EJ Tabah, FE Adair: The surgical significance of the subareolar lymph plexus in cancer of the breast. *Surgery* 33 (1953), 71-78.
12. Roumen, RMH, LM Geuskens, JGH Valkenburg: In search of the true sentinel node by different injection techniques in breast cancer patients. *Eur. J. Surg. Oncol.* 25 (1999), 347-351.
13. Kett, K, L Lukács, G Zadravec: Beitrage zur Kritik des TNM grading by Brustkrebspatienten. *Brun's Beitr. kim. Chir.* 22 (1974), 93-96.

Károly Kett, MD, PhD
County Hospital
Department of Surgery
Rákóczi u. 2.
7623 Pécs, HUNGARY H-7423