

## LYMPHOGRAPHIA

### TRANSAXIAL COMPUTER TOMOGRAPHY OF LOWER EXTREMITY LYMPHEDEMA

M. Marotel, R. Cluzan, S. Ghabboun, M. Pascot, F. Alliot, J.L. Lasry

Hôpital Saint-Michel (MM,JLL) and Hôpital Cognacq Jay (RC,SG,MP,FA), Paris, France

#### ABSTRACT

*We examined retrospectively 11 patients with isolated unilateral lower limb lymphedema (clinical criteria confirmed by isotope lymphography) using computer tomography. In conjunction with earlier observations, the findings of soft tissue stranding, skin thickening, fat deposition in the epifascial compartment and perimuscular fascial thickening and edema relate to lymph stasis. This noninvasive and relatively simple imaging technique allows analysis of soft tissue changes in leg lymphedema and can be used to evaluate lymphatic insufficiency and its extent as well as document the response to treatment.*

Computer tomography (CT) scanning in lower limb lymphedema (LE) has previously been advocated. In 1983, Gamba et al (1) described CT changes of "multiple, branching tubular structures in an enlarged subcutaneous tissue." In 1985, Hadjis et al (2), based on 12 patients with idiopathic LE, documented skin thickening, subcutaneous tissue compartment enlargement, and a characteristic "honeycombed" pattern. In 1990, Airaksinen et al (3), based on 16 patients with LE secondary to soft tissue and bony fracture injury, observed similar subcutaneous findings on CT but described decreased muscular density presumably from subfascial edema. In

1990, Vaughan (4) also described edema in the subcutaneous tissue thought to be secondary lymphedema after femoral popliteal bypass. In 1991, Bruna (5) showed a wide range of density histograms with subcutis densities in excess of -60 Hounsfield units (HU) suggesting tissue fibrosis.

To elucidate further the value of CT in peripheral lymphedema, we examined retrospectively 11 patients with isolated unilateral leg LE. Our objective was to determine if the imaging changes seen on CT directly related to mechanical lymphatic insufficiency and to provide more objective criteria for evaluating LE including later follow-up after therapy.

#### *Clinical Material*

Between 1993 and 1995, we reviewed leg CT scans of 11 patients who by clinical criteria and isotopic lymphography represented isolated unilateral secondary LE. It was assumed that perturbation images seen on the abnormal edematous leg and not depicted on the nonedematous contralateral leg were indicative of LE changes. The patients included 7 women and 5 men with a mean age of 44 years. In 3, LE was post-traumatic and in 6 was secondary to a groin operation (in 4 for lymphadenopathy, in 1 for lipoma, and in 1 for hernia repair). In

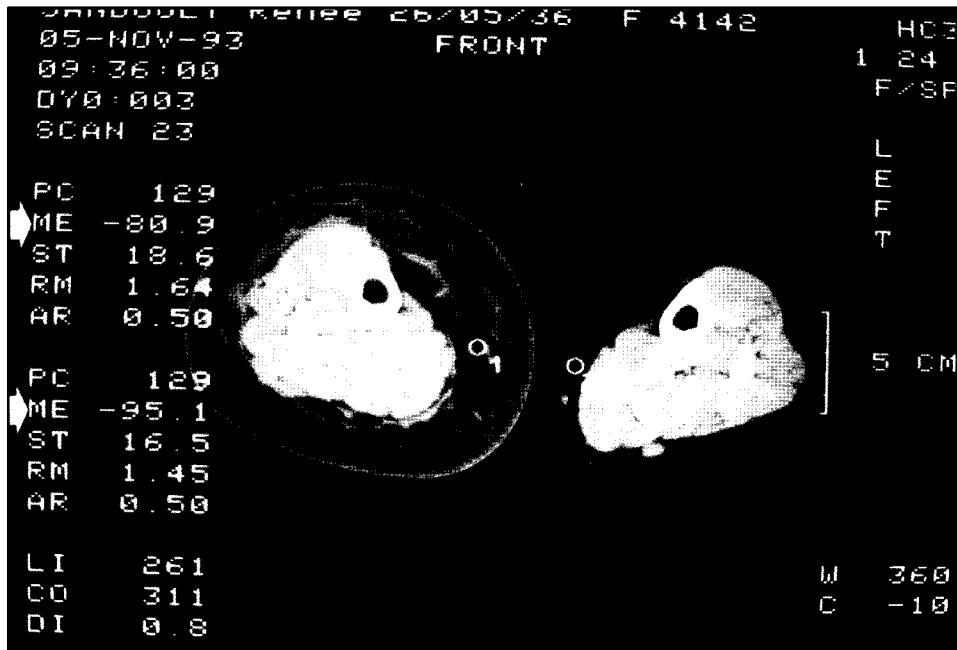


Fig. 1. CT of the lower legs showing increased soft tissue stranding, marked enlargement of the epifascial compartment in the lymphedematous leg. On the edematous side (figure left), the fat density was -80 HU compared with -95 HU on the contralateral side consistent with fat deposition. Note the subfascial compartment is similar and unremarkable in both legs. There may be early changes of LE on the contralateral side.

another patient, LE occurred after a viper snake bite and, in another, after wide resection of a thigh leiomyosarcoma.

Isotope lymphography confirmed lymphatic dysfunction in the edematous leg and was unremarkable in 10 of 11 patients in the contralateral nonedematous leg. In the other patient, interpretation of the uninvolved leg after isotope lymphogram was uncertain.

#### Technique of CT

Using a Somatom DRH Siemens unit, transaxial sections of 8 mm were made at 40 mm intervals from the groin to the ankle without injection of contrast media. Two "cuts" for area measures were made 20 cm above and 15 cm below the patella. Smooth window width and level were chosen (360/-10 HU) to examine fat content and the subfascial muscle compartment. Fat density was measured only on the CT transaxial image 15

cm inferior to the patella. Regions of interest at the level of the calf where fat does not infiltrate were examined for both sides. Using this technique, we determined the lowest representative site for fat density (Fig. 1).

By subtracting the subfascial compartment from the total transaxial image, the width of the subcutaneous compartment was determined at the level of the calf and thigh. This technique allowed comparison between the edematous and nonedematous leg including degree of skin thickening, subcutaneous compartment size, density, and appearance, perimuscular fascial thickening, and subfascial compartment size and appearance (Fig. 2).

#### RESULTS

Calf skin was thickened in 10 of 11 patients. In the other, skin thickening was detected only in the foot. In 10 of 11 patients,

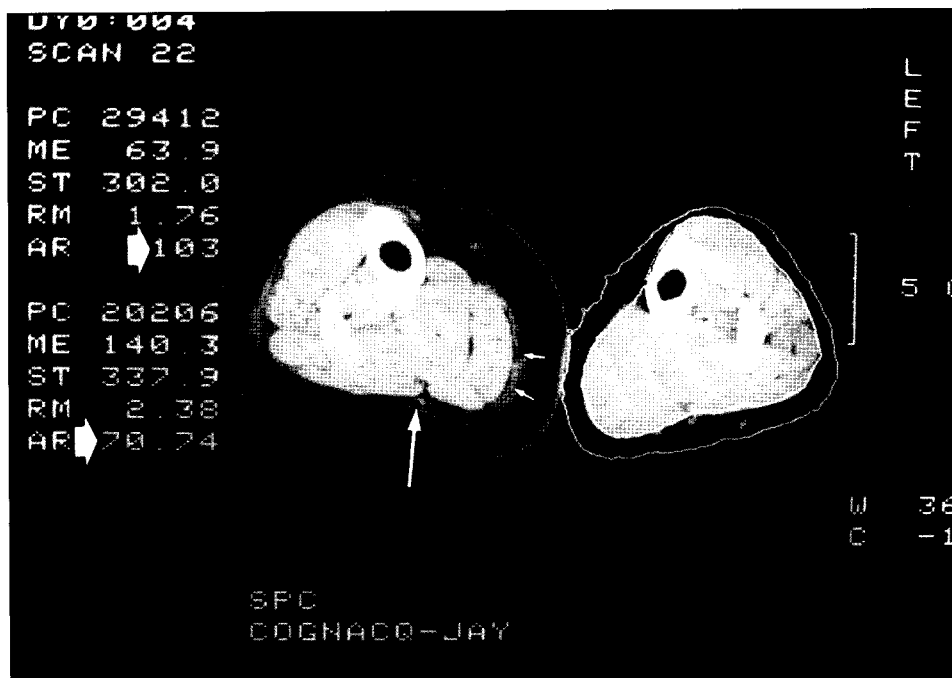


Fig. 2. CT of lower legs showing slight thickening of the skin and of the perimuscular aponeurosis (large arrow). Perimuscular edema (small arrows) and mild fat deposition in the subfascial compartment. Stranding in the subcutaneous tissue of the lymphedematous leg is minimal.

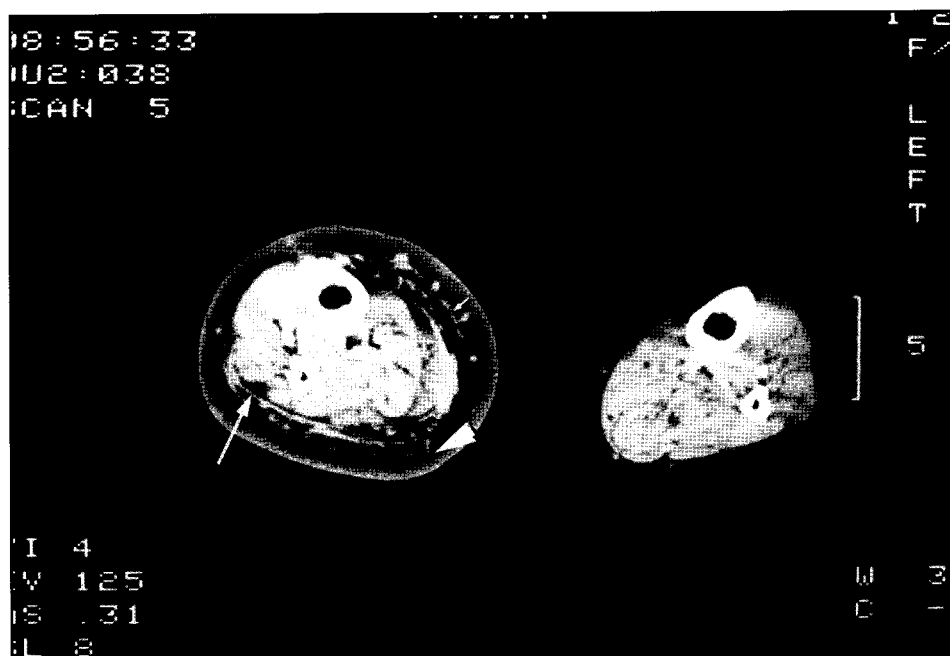


Fig. 3. CT scan of the lower legs showing marked skin thickening and subcutaneous tissue enlargement, thickening of the perimuscular fascia (large arrow), stranding parallel (small arrow), and perpendicular to the skin (arrowhead) (see Fig. 4).

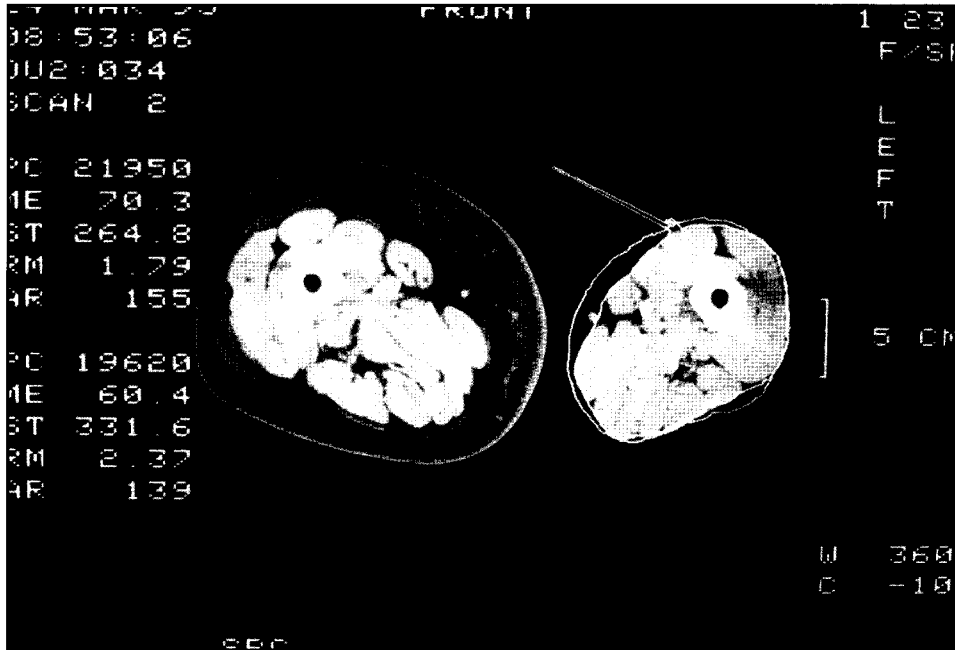


Fig. 4. CT scan of the upper legs in the same patients shown in Fig. 3 showing skin thickening, subcutaneous enlargement with stranding parallel and perpendicular to the skin on the inner thigh.

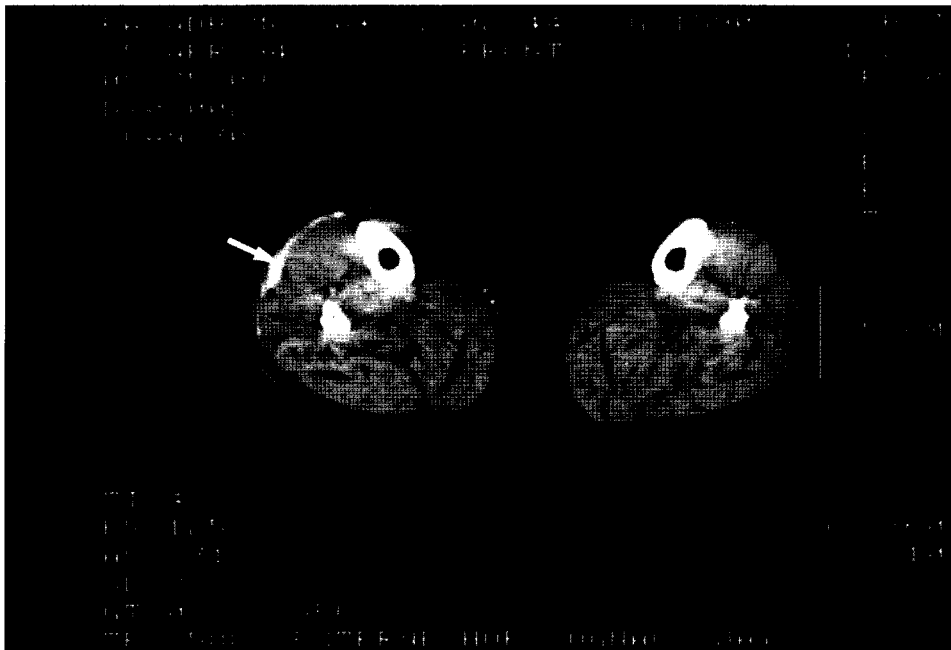
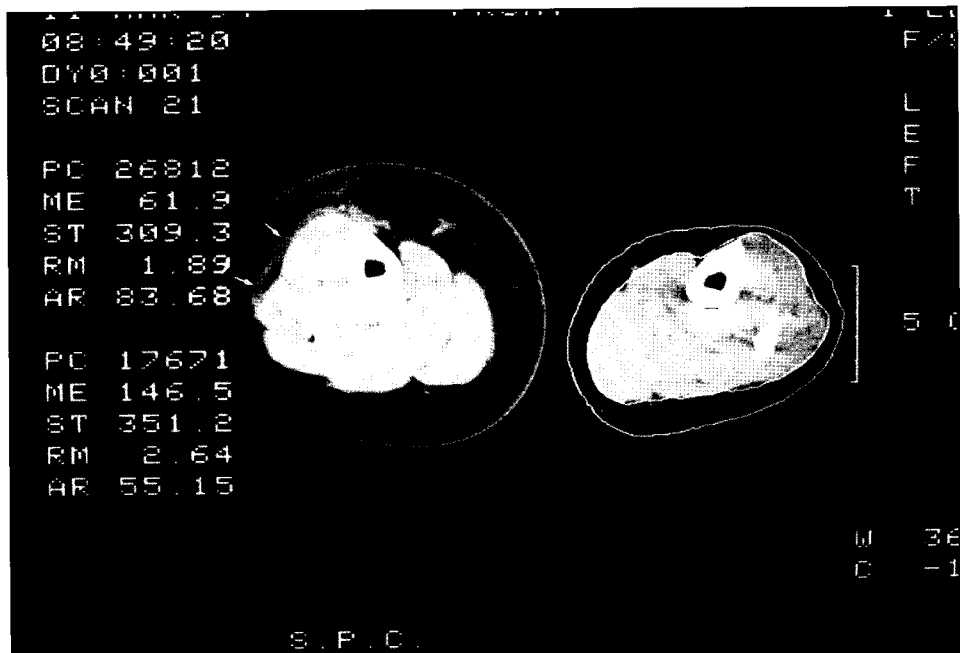
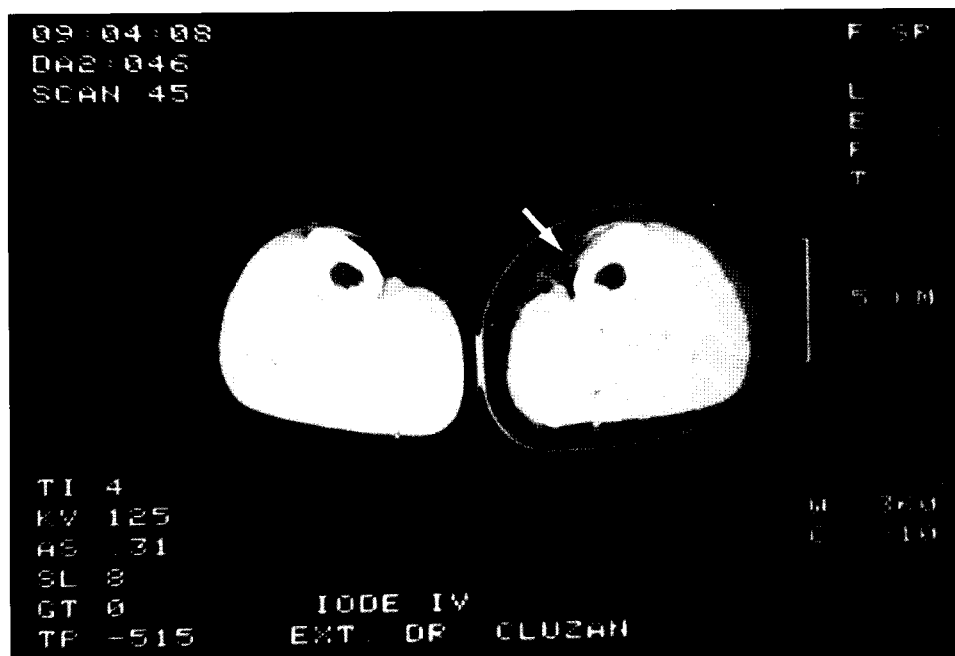


Fig. 5. CT scan of the lower legs showing marked fat deposition, calcification (arrow), and moderate enlargement of the subcutaneous tissue in the lymphedematous leg.



*Fig. 6. CT scan of the lower legs showing thickening of the skin and perimuscular aponeurosis with edema adjacent to the perimuscular fascia (small arrows) on the lymphedematous side. Several parallel and perpendicular stranding lines are seen.*



*Fig. 7. CT scan of the lower legs showing on the lymphedematous side (figure right) moderate subcutaneous tissue enlargement, edema along the perimuscular fascia and stranding parallel to the skin (arrow).*

the calf and thigh subcutaneous compartment was enlarged on the edematous side. Dramatic enlargement is shown in *Figs. 3 and 4*.

Normal fat density is approximately -130 HU. When infiltrated with denser substances such as water, macromolecules, or calcium, the fat density rises and may approach 0 HU. In 8/10 patients with leg LE, fat density was increased. When the patient was very thin, fat density measurements were difficult to determine. Overall, the mean fat density increase on the edematous side was 7.8 HU  $\pm$  6 HU with a maximum increase of 16 HU (*Fig. 5*). Edema was noted along the perimuscular aponeurosis in 7/11 patients (*Fig. 7*), with stranding paralleling the skin in 5/11 (*Fig. 8*) and stranding perpendicular to the skin in 2/11 (*Fig. 4*). The perimuscular aponeurosis was thickened in 9/11 patients (*Fig. 4*). In one patient, fascial thickening was unaccompanied by other changes whereas in 3 patients it was associated with edema and in 1 with stranding parallel and in 3 with stranding perpendicular to the skin. In one other patient, perimuscular fascial thickening with edema both parallel and perpendicular to the skin was seen. The subfascial muscular compartment was slightly enlarged on the edematous leg in 10 of 11 patients. Occasionally fat deposition between skeletal muscle bundles was depicted (*Fig. 2*).

#### COMMENT

Although CT findings vary in leg LE, which may relate to causative factors as well as to degree and duration of leg swelling, certain imaging findings are consistent. Although not invariable, enlargement of the subcutis is typical. Fat density even without other imaging findings is often increased. Thickening of the perimuscular aponeurosis is consistent with LE, and edema itself is characteristically seen in the dermis and adjacent to the perimuscular fascia but not in the subfascial compartment. Consistent with Vaughan (4), edema is primarily in the subcutaneous tissue including along the

perimuscular aponeurosis. A "honeycombed" pattern is only occasionally seen (*Figs. 4,5*). More often, stranding appears parallel or perpendicular to the skin but further apart and probably represents edema or possibly fibrosis. The subfascial compartment is mildly enlarged and occasionally relates to fat deposition between muscle bundles. Most likely, earlier descriptions of subfascial muscle atrophy with LE (3) relate to limb immobilization during fracture stabilization.

In summary, transaxial CT scanning provides a pattern of imaging changes characteristic of LE, namely, edema and fat deposition of the subcutis and edema along the perimuscular fascia. In general, the subfascial compartment is unremarkable. As a clinical tool, CT has potential to further elucidate the compartmental changes with LE and provides a baseline to document effectiveness of therapy designed to reduce tissue swelling and fibrosis.

#### REFERENCES

1. Gamba, JL, PM Silverman, D Line, et al: Primary lower extremity lymphedema: CT Diagnosis. *Radiology* 218 (1983), 149.
2. Hadjis, NS, DH Car, L Banks, et al: The role of CT in the diagnosis of primary lymphedema in the lower limb. *AJR* 144 (1985), 361-364.
3. Airaksinen, O, K Partanen, PJ Kolari, et al: Computed tomography in the evaluation of the lower leg oedema treated by intermittent pneumatic compression. In: *Progress in Lymphology-XII*. Nishi, M, W Uchino, S Yabuki (Eds.), Elsevier Science Publishers (1990), 425-428.
4. Vaughan, BF: CT of swollen legs. *Clinical Radiology* 41 (1990), 24-30.
5. Bruna, J: Computerized tomography, xeroradiography, lymphography and xerolymphography in diagnosis of lymphostasis. In: *Pathophysiology, diagnosis and treatment*. Olszewski, WL (Ed.), Boca Raton, FL: CRC Press (1991), 411-432.

**M. Marotel, M.D.**  
**Hôpital Saint-Michel**  
**33 rue Olivier de Serres**  
**75730 Paris Cedex 15, FRANCE**