

## COMBINED SURGICAL CORRECTION OF BILATERAL CONGENITAL LOWER LIMB LYMPHEDEMA WITH ASSOCIATED ANOMALIES

R. Avrahami, M. Haddad, A. Zelikovski

Department of Vascular Surgery, Rabin Medical Center (Beilinson Campus), Petah Tiqva and Sackler Faculty of Medicine, Tel Aviv University, Tel Aviv, Israel

### ABSTRACT

*An unusual combination of congenital malformations in a 16-year-old emotionally disturbed man is described. The anomalies included severe congenital bilateral leg lymphedema, bilateral gynecomastia, unilateral cataract, and malformed external genitalia. Genetic and hormonal investigations were unremarkable. Multiple concomitant operations (vascular and plastic surgeons) to correct the deformities and restore physical well-being and self-esteem were undertaken.*

Congenital lymphedema with associated malformations is well recognized (1,2). We present an unusual patient with severe bilateral leg lymphedema and a cohort of accompanying anomalies including a description of simultaneous operations to correct the deformities.

### CASE REPORT

A 16-year-old boy with massive bilateral congenital lymphedema of both legs was admitted for operation after failure to improve with manual and pneumatic lymph compression. His parents were first cousins and they had lost a child at the age of 7 months from peripheral lymphedema and chylous peritoneum. Physical examination revealed an obese patient with marked lymphedema of the legs, bilateral gyneco-

mastia (*Fig. 1*) and a "hidden penis" (i.e., the glans penis was enclosed within the scrotum). One eye displayed an "immature" cataract.

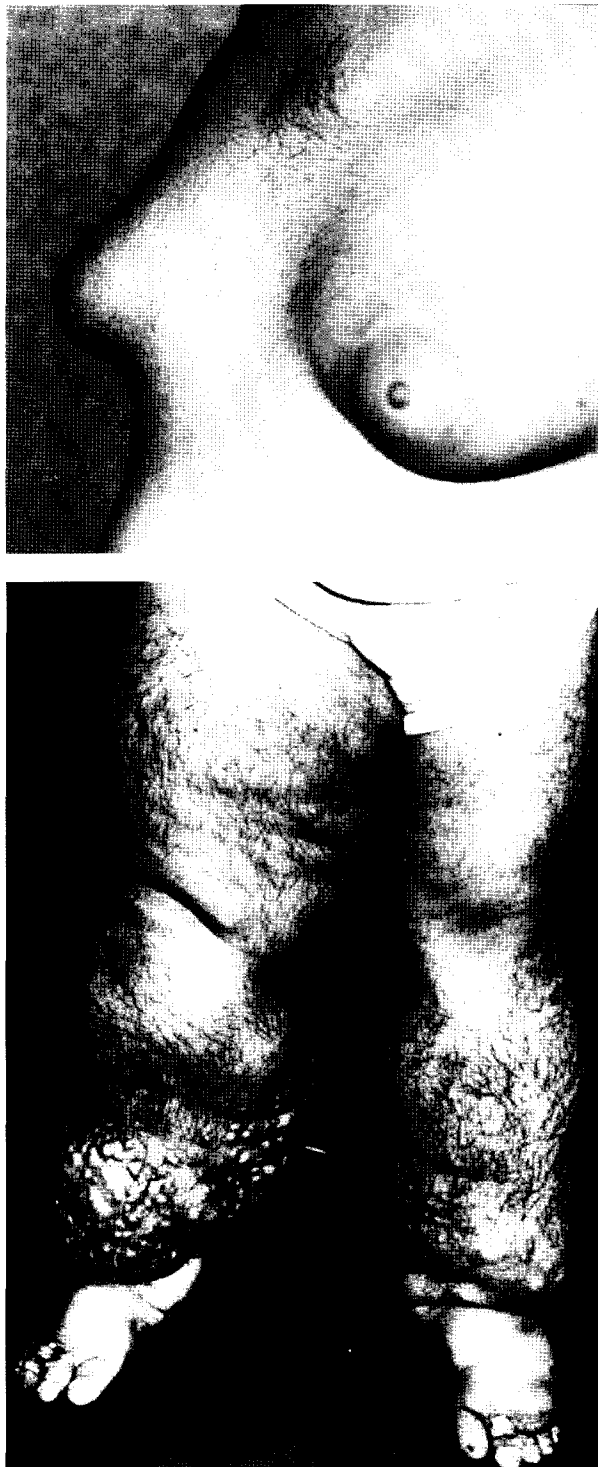Continuous intermittent pneumatic compression on both legs (Lympha-Press device) was instituted to reduce the lymphedema (3,4). After 7 days of intensive compression with improvement (*Fig. 2*), the patient was operated upon by both vascular and plastic surgeons. Debulking of the surplus skin and subcutaneous tissue of the legs was done along with correction of the gynecomastia and "hidden penis." After operation, the patient continued with Lympha-Press to minimize pain, seroma formation, and to facilitate wound healing.

The patient was discharged ten days after operation (*Fig. 3*) with firm elastic garments. Socially, his behavior had improved. A search for karyotype and hormonal abnormalities was unrewarding.

### DISCUSSION

The optimal treatment of congenital lymphedema remains unresolved. If treated properly initially with non-operative means such as mechanical and manual compression and a firm elastic support garment, giant-type lymphedema and its sequelae, including emotional behavioral consequences, may be averted. Our patient also manifested other complicating anomalies.

Sporadic reports suggest an autosomal



*Fig. 1. Sixteen year-old-man with gynecomastia (upper) and advanced congenital lymphedema (lower).*

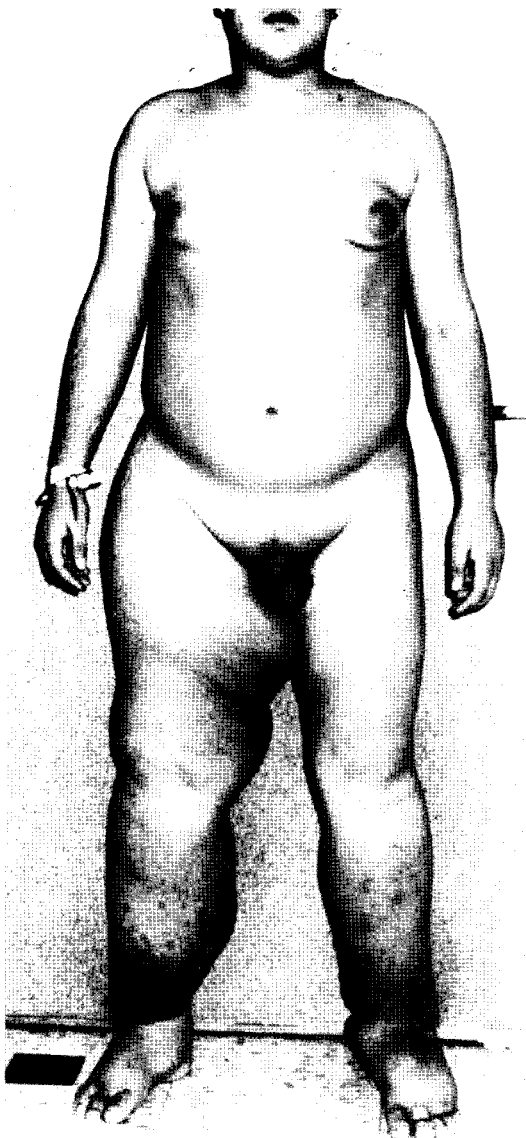
recessive-x linked form of congenital lymphedema (1,2,5,6), particularly when the latter is associated with other malformations. Although these conditions are rare and likely linked to a genetic origin, treatment has been notoriously difficult.

We specifically opted to treat the major deformities at one operative session in order to optimize patient confidence and self-esteem and thereby hoping to mollify his aggressive behavior.

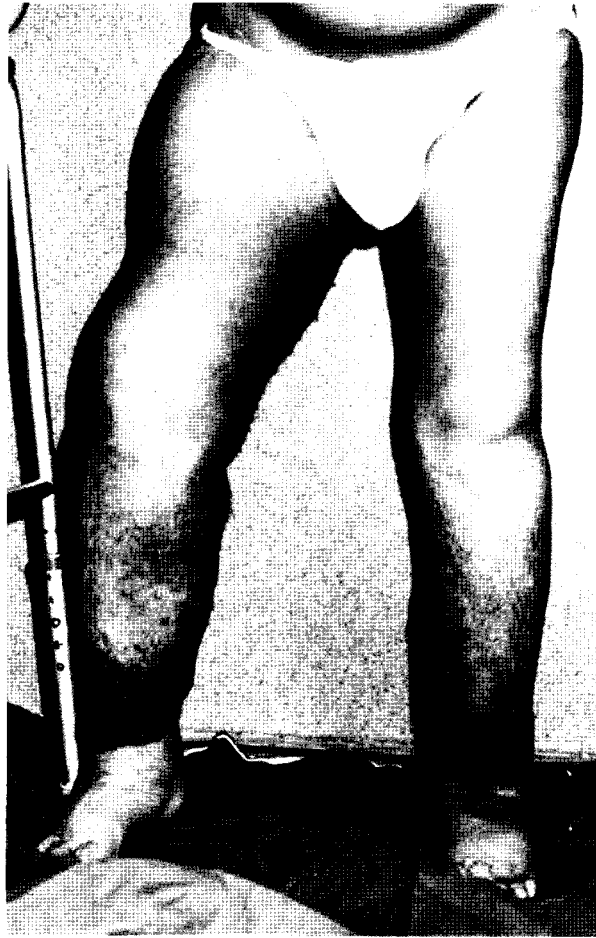Giant lymphedema in and of itself is a medical challenge. Manual compression is extremely labor intensive and takes a prolonged commitment to reduce the swelling and is likely to meet intense resistance in an emotionally disturbed young man. By contrast, vigorous treatment with pneumatic compression (Lympha-Press) over a short period with "debulking" thereafter can achieve an acceptable outcome. Correction of other malformations did not extend the operation prohibitively. Maintaining the reduction in leg swelling depends to a large extent on the patient's self-discipline, willingness to wear low stretch elastic support, and as needed, short supplemental treatments with pneumatic or manual compression.

#### REFERENCES

1. Dahlberg, PJ, WZ Borer, KI Newcomer, et al: Autosomal or X-linked recessive syndrome of congenital lymphedema, hypoparathyroidism, nephropathy, prolapsing mitral valve, and brachytelephalangy. *Am. J. Med. Genet.* 16 (1983), 99-104.
2. Mucke, J, W Hoepffner, G Scheerschmidt, et al: Early onset lymphoedema, recessive form—a new form of genetic lymphoedema syndrome. *Eur. J. Ped.* 145 (1986), 195-198.
3. Zelikovski, A, A Deutsch, R Reiss: The sequential pneumatic compression device in surgery for lymphedema in the limbs. *J. Cardiovasc. Surg.* 24 (1983), 122-126.
4. Zelikovski, A, M Haddad, R Reiss: Non-operative therapy combined with limited surgery in management of peripheral lymphedema. *Lymphology* 19 (1986), 106-108.



*Fig. 2. Improved appearance of the legs after 7 days of intermittent external pump compression (Lympha-Press).*



*Fig. 3. Appearance of legs on discharge after further operative reduction of the redundant skin and subcutaneous tissue (especially the thigh region). Correction of the gynecomastia and "hidden penis" was also done at the same operation.*

5. Kajii, T, M Tsukahara: Congenital lymphedema in two siblings. *Jpn. J. Hum. Genet.* 30 (1985), 31-34.
6. Kajii, T, M Tsukahara: Autosomal recessive lymphedema? (Letter). *Jpn. J. Ped.* 31 (1986), 57.

**A. Zelikovski, M.D.**  
**Department of Vascular Surgery**  
**Rabin Medical Center (Beilinson Campus)**  
**Petah Tiqva, 49100, ISRAEL**  
**Telephone: 972-3-976666**  
**Fax: 972-3-9376678**

## LYMPHATIC DRAINAGE REDUCES INTESTINAL EDEMA AND FLUID LOSS

R.E. Drake, R.A. Teague, J.C. Gabel

Departments of Anesthesiology, The University of Texas-Houston Medical School, Houston, Texas and the UCLA School of Medicine, Los Angeles, California, USA

### ABSTRACT

*Lymphatic vessels are important in removing excess fluid from the intestine and transporting the fluid to veins in the neck. However, in some diseases, neck vein pressure is increased and the high pressures may slow lymph flow. This study was to test the hypothesis that lymphatic clearance of fluid from the intestine may be increased by draining the lymphatics. Inflatable cuffs were used to increase neck vein pressure and portal venous pressure in anesthetized sheep. The lymphatic vessel from one segment of small intestine was cannulated and drained. The lymphatic vessel to a control segment of intestine was left intact. After 90 min. we found significantly less fluid in the lumen of the drained vs. control segments ( $7.4 \pm 3.1$  (SD) ml vs  $11.5 \pm 4.7$  ml per gram dry tissue, respectively). Also we found significantly less tissue fluid in the drained vs control segments ( $5.3 \pm 0.3$  ml/g vs  $6.0 \pm 0.4$  ml/g). The findings support the hypothesis that external diversion of lymph in the presence of an elevated central venous pressure reduces edema formation.*

Lymphatic vessels play an important role in preventing edema because they remove excess fluid from the tissue of most organs. Normally fluid filters from the blood capillaries and into the tissue spaces. Lymphatic vessels remove the fluid from the tissues and transport it to large lymphatic trunks such as

the thoracic duct. The thoracic duct drains the fluid to veins within the neck. If capillary filtration rate is increased, lymph flow must increase to remove the excess fluid. If lymph flow does not increase as much as capillary filtration increases, some of the capillary filtrate will accumulate within the tissue as edema fluid.

The elevated venous pressure associated with right heart failure places a double burden on the lymphatic vessels (1). First, the high venous pressure causes increased capillary filtration throughout the body. Second, the high pressure in the neck veins opposes lymphatic drainage. Thus the lymphatic vessels must transport an increased fluid load against an increased outflow pressure. Often the lymphatics fail, and edema develops.

One way to improve lymph flow in heart failure is to drain the thoracic duct. Investigators have cannulated the duct and allowed it to drain freely or they have anastomosed the duct to low pressure vessels in animals or patients with heart failure (1-4). The thoracic duct drainage reduced or eliminated edema. However, the reduced edema cannot be attributed solely to lymphatic drainage of edema because, in many cases, venous pressure decreased. Thus capillary filtration may have decreased. Our aim in this study was to test the effect of external lymphatic drainage on intestinal edema in sheep with right heart failure and constant portal venous pressure.

## METHODS

We anesthetized 5 sheep (36-43 kg) with thiopental sodium, placed a tracheotomy tube and ventilated the sheep with 30% O<sub>2</sub> in air. We cannulated a jugular vein and a femoral artery. Then we opened the right chest above the heart and placed inflatable cuffs around the inferior and superior vena cava. We made a midline abdominal incision to expose the small intestine, and we placed a cannula into the portal vein. Then we identified three ~30 cm long segments of intestine. We ligated one end of each segment and gently milked the lumen contents from the segment. Then we ligated the opposite end of the segment. The segments were identified as baseline, control and drained segments. We chose intestinal segments with easily defined prenodal lymphatic vessels that drained to different lymph nodes. The segments were treated as described below:

- 1) The baseline segment was removed, and the volume of fluid in the lumen and tissue was determined.
- 2) We cannulated the postnodal lymphatic for the drained segment.
- 3) We confirmed there were no postnodal lymphatics from the control segment that ran to the node serving the drained segment. We left the lymphatics from the control segment intact.

We used solid state pressure transducers to monitor neck vein and portal vein pressure, and aortic pressure. In our preparation the intestinal segments were approximately level with the right atrium of the heart, and we set the zero pressure reference level at the intestinal segments. Blood samples were taken each 30 min. for estimate of hematocrit and plasma protein concentration. Protein concentration was estimated with an American Optical refractometer, and we used a membrane osmometer to determine the plasma protein osmotic pressure.

## The Experiments

First we inflated the cuff around the superior vena cava and elevated neck vein pressure to 35-40 cmH<sub>2</sub>O (baseline = 0-5 cmH<sub>2</sub>O). Then we inflated the inferior vena caval cuff. Because the inferior vena caval cuff was between the hepatic veins and the heart, portal venous pressure increased. We used an electromechanical system to regulate cuff inflation and control portal venous pressure (5).

As soon as we elevated the venous pressures, we placed the lymphatic cannula from the drained segment into a beaker located ~ 25 cm. below the intestine. Thus lymph drained freely into the beaker. Each 15 min. we removed the cannula from the beaker, placed the cannula tip into a calibrated pipette and timed the lymph flow rate ( $Q_L$ ). After each  $Q_L$  determination, we poured the lymph from the pipette into the beaker. The total volume of drained lymph was determined as the volume of fluid in the beaker at the end of the experiment.

We maintained the neck and portal venous pressures elevated for 90 min, then we euthanized the sheep and removed the control and drained segments of intestine.

### Intestinal Fluid Volume

To determine the volume of fluid in the lumen of the intestinal segments, we cut the end of each segment and drained the fluid into a pan. The amount of fluid was estimated by weighing the pan. Once we had drained all fluid from the lumen, we weighed each intestinal segment (wet weight). The segments were dried to constant weight in an oven at 60°. To calculate the amount of fluid in the tissue of each segment, we subtracted the dried segment weight from the segment wet weight. To account for differences in segment size, fluid volumes were normalized with segment dry weight.

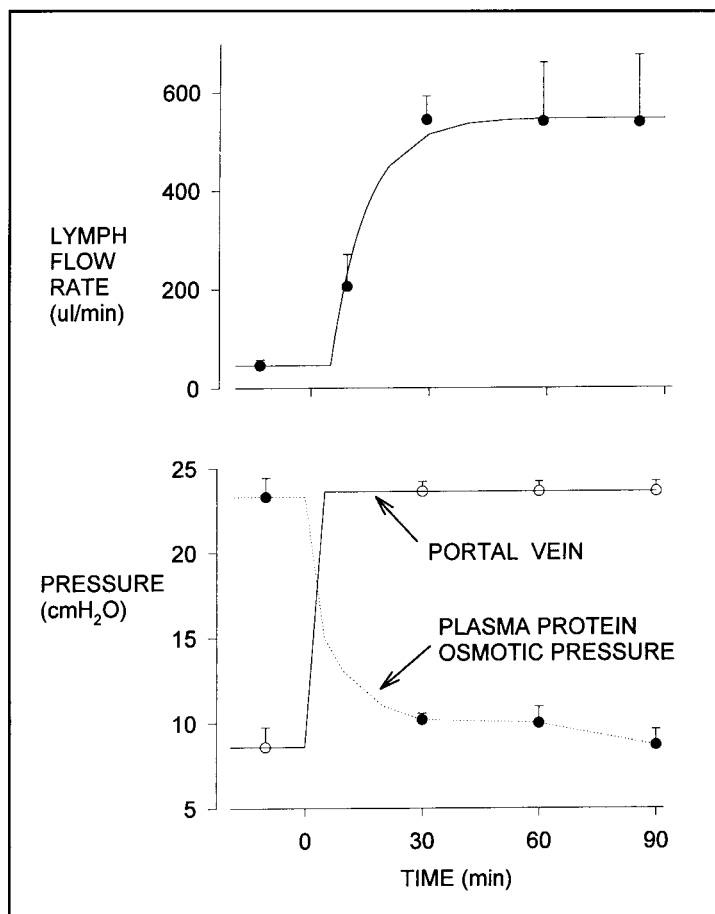


Fig. 1. Lymph flow rate (upper panel), portal vein pressure and plasma protein osmotic pressure (lower panel) vs time for all sheep.

### Statistics

Data are mean  $\pm$  SD in the text and mean  $\pm$  SE in figures. We used student's t-test to test for differences in data.  $P < 0.05$  was accepted to indicate significant differences.

### RESULTS

The initial neck vein pressure =  $2.8 \pm 0.8$  cmH<sub>2</sub>O and it increased to  $36 \pm 3$  cmH<sub>2</sub>O when we inflated the cuff around the superior vena cava. As shown in Fig. 1, portal venous pressure increased from  $8.6 \pm 2.6$  to  $23.5 \pm 1.4$  cmH<sub>2</sub>O when we inflated the inferior vena caval cuff. When we inflated the vena caval cuffs, blood pooled within the veins and

venous return to the heart was reduced. Also, the high venous pressures caused considerable fluid loss from the vascular to the extravascular compartments. Thus, to maintain intravascular volume and cardiac output, we infused  $5,400 \pm 1,100$  ml of warmed Ringer's solution intravenously. This volume infusion caused plasma protein concentration to decrease from  $4.9 \pm 0.4$  g/dl at baseline to  $2.2 \pm 0.4$  g/dl at 90 min. The decrease in plasma protein concentration accounts for the decrease in plasma protein osmotic pressure shown in the lower panel of Fig. 1. Hematocrit decreased from  $33 \pm 4\%$  to  $25 \pm 6\%$ .

At baseline,  $Q_L = 46 \pm 26$  ul/min and as shown in Fig. 1,  $Q_L$  increased substantially when we increased portal venous pressure.

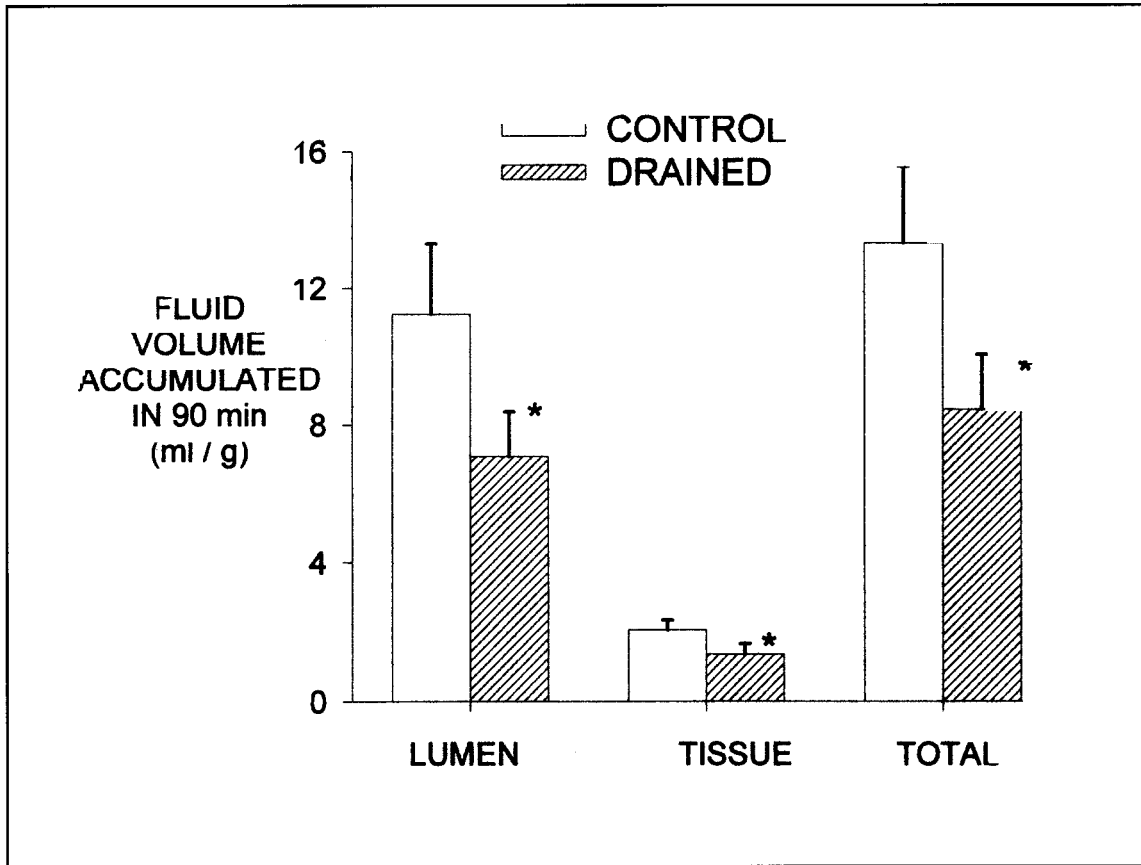


Fig. 2. Fluid accumulation in the lumen and tissue spaces and total fluid accumulation for the control and drained segments. Fluid accumulation was calculated as the amount of fluid in the control or drained segments at the end of the 90 min. period of elevated venous pressure minus the amount of fluid in the baseline intestinal segment. Asterisk (\*) indicates data for drained segment significantly less than control ( $P < 0.05$ ).

We collected a total of  $49 \pm 29$  ml of lymph during the 90 min. experiment period.

The baseline intestinal segment lumen fluid volume was  $0.28 \pm 0.41$  ml per g dry weight. (As expected, the baseline lumen fluid volume was almost zero because we emptied the lumen fluid from the segment only 10-20 min. before we removed the segment.) Lumen fluid volumes for the control and drained segments ( $11.5 \pm 4.7$  and  $7.4 \pm 3.1$  ml/g respectively) were significantly greater than the baseline segment fluid volume. Similarly the tissue fluid volumes for the control and drained segments ( $6.0 \pm 0.4$  and  $5.3 \pm 0.3$  ml/g respectively) were significantly greater

than the baseline segment tissue fluid of  $4.0 \pm 0.4$  ml/g.

The baseline fluid volumes are our estimates of the volumes before we increased the venous pressures. The control segment fluid volumes are the fluid volumes after the 90 min. period of elevated pressure. Thus to estimate the amount of fluid that accumulated in the control segment during the 90 min. period of elevated pressures, we subtracted the baseline fluid volumes from the control segment fluid volumes. Similarly to estimate the amount of fluid accumulation in the drained segments, we subtracted the amount of fluid in the baseline segments from

the amount of fluid in the drained segments. The results of these calculations are shown in *Fig. 2* in which we have plotted the volume of fluid which accumulated in the control and drained segments over the 90 min. period of elevated venous pressures. As shown in *Fig. 2*, significantly less fluid accumulated in the tissue spaces and in the lumen of the drained vs. control segments. Furthermore the total fluid accumulation (tissue fluid + lumen fluid) was significantly less in the drained vs. control segments.

### DISCUSSION

Our results support the hypothesis that intestinal lymphatic clearance may be improved by external lymphatic drainage (1-4). Because the lymphatic vessels from the control intestinal segments in our sheep were intact, lymph flow from those segments was opposed by the high neck vein pressure. On the other hand, neck vein pressure had no effect on lymph flow from the drained segments because the lymph from those segments drained freely into a beaker. We believe the greater lymphatic clearance in the drained (vs. control) segments accounts for the significantly lower amount of fluid in the drained segments.

The high neck vein pressure was the main factor opposing lymph flow from the control segments in our sheep. However, in addition, lymphatic resistance may have reduced lymph flow (3,6). Lymph from the control segments drained from the nodes, through 20-30 cm of postnodal intestinal lymphatic and through the thoracic duct before it entered the veins. Other investigators have noted the resistance to flow at the thoracic duct - neck vein junction may interfere with lymph flow (3,6). Thus the resistance to lymph flow may have impeded lymph flow from the control intestinal segment. We do not believe resistance interfered with lymph flow from the drained segments. We cannulated lymphatics from the drained segments with 0.76 mm inside

diameter silastic tubing. However, to minimize resistance, we cut the cannula near the vessel and connected the cannula to larger diameter tubing (2 mm inside diameter). Furthermore we placed the outflow end of the cannula ~ 25 cm below the intestinal segment.

Postnodal intestinal lymphatic vessels actively pump lymph toward the neck veins (7,8). This pumping activity is due to spontaneous contraction of the lymphatic vessel smooth muscle. Many investigators have shown that pumping increases as the pressure at the outflow end of the lymphatic is increased. This phenomenon helps to maintain lymph flow in spite of increased outflow pressure. However, active pumping is less effective in driving lymph against high outflow pressures when lymph flow is increased (9,10). Lymph formation was greatly increased in our sheep. Furthermore, active pumping may be weakened in anesthetized sheep. Thus it is unlikely the active lymphatic pump could have maintained a maximum flow rate from the control segments in our sheep.

We increased portal venous pressure in our sheep because we wanted to increase capillary filtration rate and challenge the lymphatics. According to the Starling hypothesis, the total intravascular pressure causing fluid filtration is the capillary hydrostatic pressure minus plasma protein osmotic pressure. As shown in *Fig. 1*, plasma protein osmotic pressure decreased substantially. Thus the increase in capillary filtration rate resulted from both the increase in hydrostatic pressure and the decrease in osmotic pressure.

As shown in *Fig. 2*, much more fluid accumulated within the intestinal lumen than in the tissues. Thus most of the capillary filtrate flowed through the tissue spaces, across the mucosa and into the lumen. Both tissue fluid and lumen fluid were less in drained vs. control segments. However, lymphatics drain only from the tissues. Thus, in drained segments, the lymphatic vessels probably siphoned some of the capillary



filtrate as it passed through the tissue spaces toward the lumen. In addition to the tissue fluid and lumen fluid, some fluid wept from the surface of the intestine in our sheep. We could not quantitate this fluid, but it was much less than the lumen fluid volume.

Our results support the findings by other investigators that edema may be reduced by draining the thoracic duct (1-4). Our study differs from previous studies because we maintained venous pressure constant. Furthermore, we drained a lymphatic from a specific organ whereas the thoracic duct drained by other investigators carries lymph from most of the body.

#### ACKNOWLEDGMENT

The authors thank Caroline Buggs-Warner for typing this manuscript. The work was supported by the National Institutes of Health Grants HL-49424 and DK-41859.

#### REFERENCES

1. Witte, M.H., AE Dumont, RH Claus, et al: Lymph circulation in congestive heart failure. Effect of external thoracic duct drainage. *Circulation*. 39 (1969), 723-733.
2. Cole, WR, MH Witte, SL Kash, et al: Thoracic duct-to-pulmonary vein shunt in the treatment of experimental right heart failure. *Circulation*. 36 (1967), 539-543.
3. Dumont, AE, JH Mulholland: Effect of thoracic duct to esophagus shunt in dogs with vena caval constriction. *Am. J. Physiol*. 204 (1963), 289-290.
4. Witte, MH, W R Cole: Failure of lymph flow in man and experimental animals: reversal by surgically constructed lymphatic venous shunts. In: *Progress in Lymphology*. Proceedings of the International Symposium on Lymphology. Ruttimann A (Ed.), Georg Thieme Verlag, Stuttgart, Publ., 1967, pp. 376-379.
5. Drake, RE, DK Adcock, RL Scott, et al: A feedback system to control blood flow in dog lung lobes. *J. Appl. Physiol*. 53 (1982), 1650-1652.
6. Dumont, AE: The flow capacity of the thoracic duct-venous junction. *The Am. J. of the Med. Sci*. 269 (1975), 292-301.
7. Benoit, JN, DC Zawieja: Effects of f-Met-Leu-Phe-induced inflammation on intestinal lymph flow and lymphatic pump behavior. *Am. J. Physiol*. 262 (1992), G199-G202.
8. Johnston, MG, JL Gordon: Regulation of lymphatic contractility by arachidonate metabolites. *Nature*. 293 (1981), 294-297.
9. Drake, RE, JC Gabel: Effect of outflow pressure on intestinal lymph flow in unanesthetized sheep. *Am. J. Physiol*. 260 (1991), R668-R671.
10. Drake, RE, D Weiss, JC Gabel: Active lymphatic pumping and sheep lung lymph flow. *J. Appl. Physiol*. 71 (1991), 99-103.

**Robert E. Drake, Ph.D.**  
**The University of Texas-Houston Medical School**  
**Department of Anesthesiology**  
**6431 Fannin, MSB 5.020**  
**Houston, TX 77030**  
**Phone: 713/500-6235**  
**Fax: 713/500-6201**