

SKIN BLOOD FLOW OF THE LYMPHEDEMATOUS ARM BEFORE AND AFTER LIPOSUCTION

H. Brorson, H. Svensson

Department of Plastic and Reconstructive Surgery, Malmö University Hospital, Malmö, Sweden

ABSTRACT

Twelve women with arm lymphedema after breast cancer treatment underwent liposuction followed by external compression with a garment-sleeve. Arm volumes were measured using water displacement technique, and skin blood flow was recorded with laser Doppler imaging (LDI). Data was collected before and after (3 and 12 months) liposuction. Episodes of cellulitis were also recorded.

Whereas previous investigations have indicated increased total blood flow in the lymphedematous arm, we found reduced superficial skin blood flow preoperatively. Liposuction produced a median edema reduction of 87% and 97% after 3 and 12 months respectively. Both in the forearm and in the upper arm, skin blood flow increased significantly after liposuction and values were similar to those of the non-edematous (control) arm. Along with increased skin blood flow, the frequency of cellulitis also decreased.

Liposuction effectively reduces arm lymphedema after breast cancer treatment, and also lowers the incidence of arm cellulitis. Improved local skin blood flow may be an important contributing factor to the reduced episodes of arm infection.

The rate of filtration along a capillary depends upon the filtration pressure gradient, i.e., the hydrostatic pressure in the capillary minus the hydrostatic pressure of the interstitial fluid. The filtration pressure is

counteracted by the inwardly directed protein osmotic gradient, due to the presence of large amounts of proteins in the blood plasma, viz. oncotic pressure. Normally, fluid moves into the interstitial space at the arteriolar end of the capillary, and back into the capillary at the venular end. Fluid efflux, however, slightly exceeds influx across the capillary membrane and the net filtrate enters lymphatics and drains back to the bloodstream. The tissue fluid-lymph circulation keeps the interstitial pressure stable.

Breast cancer treatment typically includes excision of axillary lymph nodes as staging and often radiotherapy for eradication of regional tumor spread. Both measures interfere with normal lymph drainage from the arm, and subcutaneous arm lymphedema commonly ensues. The incidence of arm lymphedema varies between 8% and 38% depending upon whether or not axillary lymph nodes are excised and radiation therapy is administered (1). Accumulation of interstitial fluid gradually increases tissue pressure and thereby reduces (counterbalances) the filtration pressure gradient. Excess tissue fluid also reduces the protein osmotic gradient by virtue of an increased accumulation of osmotically active macromolecules that derive from plasma filtration. Both effects interfere with the normal turnover of interstitial fluid. Over time, subcutaneous lymphedema becomes firm and more dense. Probably pinocytosis of white blood cells, in combination with activation of

fibrocytes, increases the connective tissue component of the primordial loose subcutaneous fat. It is not completely understood how these phenomena alter the skin microcirculation, or how microcirculatory changes themselves influence lymphedema.

Clinically, the aforementioned sequence of events leading to subcutaneous tissue lymphedema becomes a vicious circle, and various operative methods have been designed to reverse edema progression after breast cancer treatment. The results have been equivocal and/or unpredictable but a contemporary promising method is liposuction. In a previous study using this technique combined with postoperative compression therapy, we reported that normalization of arm volume was achieved and maintained even with advanced lymphedema (2). Additionally, the incidence of local skin infection also decreased after liposuction.

We now compared skin microvascular blood flow in the normal compared with the lymphedematous arm before and after liposuction of the edematous arm. For this purpose, we utilized a novel laser Doppler imaging technique.

MATERIALS AND METHODS

Patients

Twelve women with unilateral arm lymphedema underwent liposuction and participated in the blood flow study, which is part of our standard treatment protocol for patients undergoing major limb reconstruction. Each had previously undergone mastectomy with sampling of axillary lymph nodes, supplemented with postoperative radiation therapy for treatment of breast cancer. The median age was 62 years (range 47-81). The interval between primary breast surgery and liposuction was 8 years (range 1-17), on average, and between the occurrence of lymphedema and liposuction, 6 years (range 1-16). Indication for liposuction was

the subjective discomfort of a heavy arm, and the fact that treatments with compression pumping and/or manual lymph therapy had not yielded satisfactory edema reduction. The mean arm edema volume before liposuction was 1,925 ml (range 810-3,915).

Operative Procedure

A detailed description of the liposuction procedure has been published (2). In brief, short, blunt cannulas (outer diameter of 3-4 mm and 2-3 openings distally) were used through 3 mm skin incisions. The whole arm was treated circumferentially, starting distally. Immediately postoperatively, external pressure was applied with bandages, which were later replaced by an interim dressing, and subsequently by a custom-made compression garment (Jobst®-Beiersdorf). This garment was then worn permanently.

Measurements

Arm volumes were recorded in ml using water displacement technique as previously described (2-5). Both arms were measured so that edema volumes could be calculated before and after liposuction.

Skin blood flow was measured using laser Doppler imaging, LDI (Lisca Development AB, Linköping, Sweden). Light is directed onto the tissue by means of a scanner system consisting of two stepping motors and mirrors. The backscattered light is detected by a remote photodiode. An electrical signal that scales linearly with the number of Doppler-shifted beams and the average Doppler frequency shift is then generated. This technique is done for each measuring step, where one step takes approximately 50 milliseconds to perform. After the signal has been processed, the data are stored in a computer and the images produced using a color printer on a scale from dark blue to red, related to increasing flow. The total amount of backscattered light is also measured in order to distinguish the background (low light

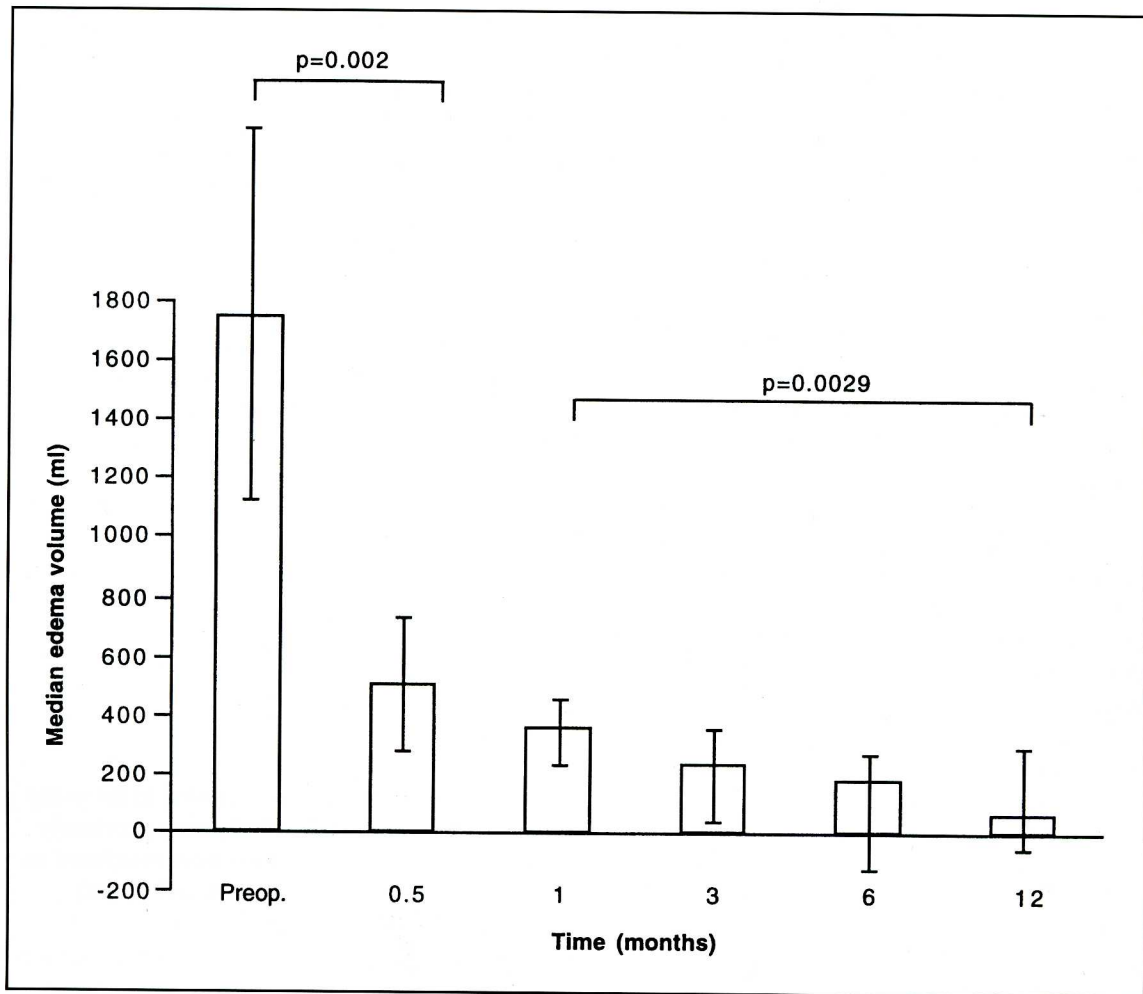


Fig.1. Median edema volume and 25 and 75 percentiles pre- and postoperatively in 12 patients. Note the pronounced effect after liposuction and that improvement in edema continues significantly in the subsequent postoperative course.

intensity) from no-flow areas (high light intensity), which both generate backscattered light without any Doppler shifts. LDI values were recorded in volts (V).

Before liposuction, and 3 and 12 months afterwards, skin blood flow was determined in both arms using LDI. Each measurement was performed in a room at constant temperature ($23.4 \pm 0.8^\circ\text{C}$). The patients were seated comfortably in a chair with the forearm resting on a table. A 15 min period was allowed for acclimatization. During measurements after operation, the compres-

sion garment was removed. Measurements began with the non-edematous contralateral arm, which served as a control. The dorsal aspects of the hand and forearm and the lateral aspect of the upper arm were measured. The device was positioned 17 cm above the skin surface. Measurements were obtained from about 4,096 points, corresponding to an area of 12 x 12 cm. Each image took 4 min to record. The recordings from the operated arm were made approximately 20 min after removal of the compression garment.

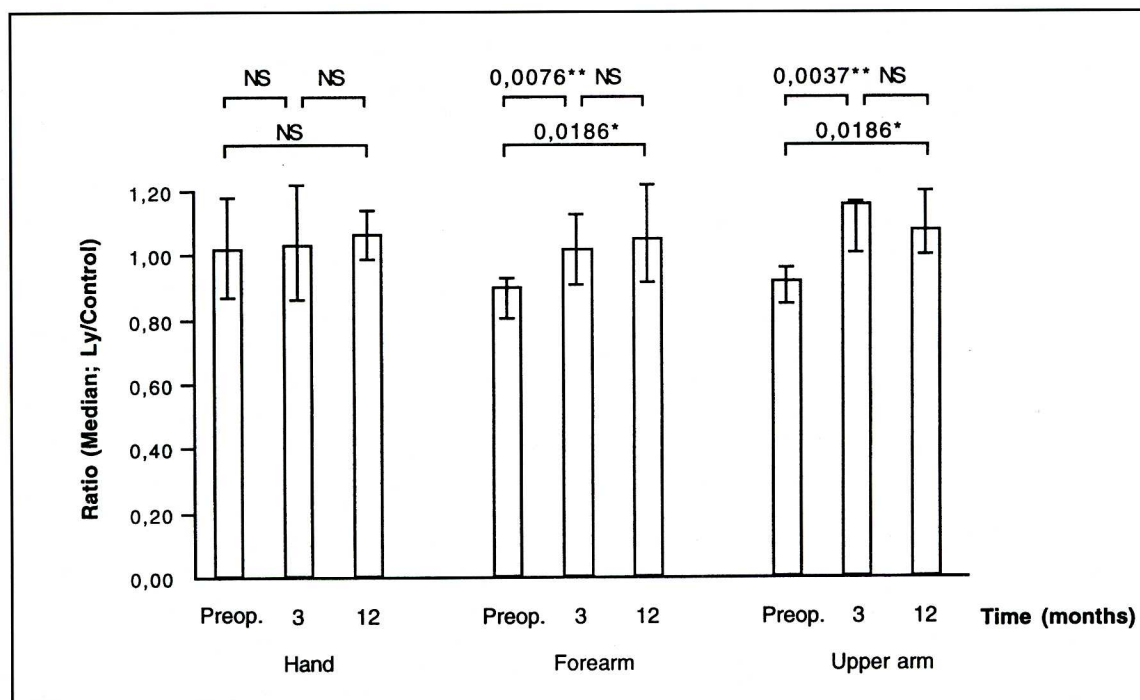


Fig. 2. Median lymphedema arm/control (ly/control) arm ratios in 12 operated patients showing that skin blood flow significantly increased postoperatively at both 3 and 12 months, compared with the preoperative values in the forearm and upper arm, but not in the hand. Error bars show 25 and 75 percentiles (Wilcoxon signed rank test).

Clinical Evaluation

The patients were evaluated preoperatively and then followed in the outpatient unit by a lymphedema team consisting of a plastic surgeon (HB), a physiotherapist, an occupational therapist, and a social welfare officer. Besides measurements, the medical history was carefully taken at each visit. Although the data reported regarding volume changes and skin blood flow were after 3 and 12 months, the clinical evaluation continued and the present follow-up time is now 29 months (range 26-35).

Calculation and Statistical Analysis

Values are presented as median and ranges unless otherwise indicated. For each patient, the ratio between LDI values from the lymphedematous and the non-edematous

(healthy) arm was calculated. A ratio <1.0 denotes decreased skin blood flow in the lymphedematous arm, compared with the normal arm. The Wilcoxon signed-rank test was used for statistical analyses.

The preoperative incidence of cellulitis was calculated as the accumulated number of cellulitis episodes divided by the accumulated duration of arm edema. The postoperative incidence was calculated as the accumulated number of cellulitis episodes divided by the accumulated duration of postoperative observation.

RESULTS

There were no notable surgical complications. Blood transfusion was necessary in 4 patients where aspirated volumes exceeded 2000 ml. Eleven of the 12 patients had no signs of retained tumor. One had had two

local subcutaneous glandular metastases excised from the adipose tissue in the upper arm. She later developed generalized metastatic disease.

Volumes

The median preoperative arm volume difference was 1,745 ml (range: 810-3,915). Liposuction aimed to eliminate surplus tissue completely and the median aspirated volume was 2,060 ml (1000-3850). The arm volume difference at 3 months was only 230 ml (range: -185-1960 ml), and at 12 months it further declined to a mere 60 ml (range: -445-1135). These figures correspond to a relative edema reduction of 87% and 97%, respectively (*Fig. 1*).

Skin Blood Flow

Median LDI values before liposuction from the lymphedematous arm were 1.64 in the hand, 0.91 in the forearm, and 0.93 in the upper arm. Corresponding values from the control limb were 1.80, 1.09, and 0.99. The preoperative median LDI ratios were 1.01, 0.90, and 0.92, respectively. Significantly increased skin blood flow was measured in the lymphedematous arm after liposuction, but not in the hand. Median LDI ratios were 1.03, 1.01, and 1.15 at 3 months, and 1.06, 1.05, and 1.07 at 12 months (*Table 1, Fig. 2*).

Cellulitis

Cellulitis was defined as a marked reddening of the arm skin requiring antibiotics. The annual incidence of cellulitis was 0.4 (40/97) before liposuction and 0.1 (3/30) after liposuction.

DISCUSSION

Laser Doppler Imaging (LDI)

LDI measures linearly the 'blood cell flux,' i.e., the movements of blood cells

within the microvascular network of the skin (6,7). Although LDI cannot be used to measure skin blood flow quantitatively, it has proved useful for monitoring relative changes in various physiologic and pathophysiological conditions (8,9). Flow completely obstructed by arterial occlusion gives a remaining signal which, though weak, does not fall to an electrical zero, because the instrument is equipped with an electrical zero offset to prevent negative values from occurring in the images. Another contributory factor is a "biological zero" most likely from randomized cell and tissue movements (10). It is uncertain, however, whether the phenomena responsible for the biological zero occurs with normal perfusion. It may simply reflect an obstructed bloodstream. Furthermore, arterial occlusion is impractical in the present clinical experimental set-up. Taking these considerations into account, we opted to study changes in skin blood flow by LDI without calibrating to an arterial occlusion value.

Compared with single-site measurements using the original laser Doppler flowmetry method, LDI provides a new and broader dimension. By using several measuring sites, a more reliable recording is obtained when the mean flow is estimated in a defined tissue, such as the arm or hand skin as in this study. One potential drawback (not directly applicable to this study) is that scanning is time consuming, and rapid changes in blood flow over larger skin areas are not able to be monitored.

The measuring depth of LDI depends on particular instrumental factors, such as, for example, the wavelength. Recent investigations using Monte Carlo simulation suggest a rather shallow average median sampling depth of about 0.3 mm in the scattering volume, which corresponds to the superficial capillaries only (11). Although the measuring depth is influenced by absorption and scattering properties in various tissues, the most important tissue-related factor that must be taken into account is the vascular geometry. Arteriovenous shunts and vascular

TABLE 1
Arm Volumes (ml), LDI* Values (P.U. or Perfusion Units) and
LDI Ratios (Median and Ranges) Before and After Liposuction

	Before	Liposuction	
		3 months	12 months
Arm volume difference (ml)	1745 (810-3915)	230 (-185-1960)	60 (-445-1135)
LDI values (P.U.)			
Lymphedema arm			
Hand	1.64 (0.88-2.75)	1.73 (1.25-4.31)	1.61 (1.12-3.71)
Forearm	0.91 (0.64-2.44)	1.06 (0.84-1.35)	1.23 (0.96-1.94)
Upper arm	0.93 (0.57-1.70)	0.93 (0.79-1.10)	1.06 (0.77-1.66)
LDI values (P.U.)			
Contralateral arm			
Hand	1.80 (0.92-2.65)	1.76 (1.38-2.96)	1.66 (1.01-3.19)
Forearm	1.09 (0.78-2.46)	1.03 (0.85-1.37)	1.16 (0.95-1.77)
Upper arm	0.99 (0.64-2.14)	0.88 (0.69-0.94)	1.01 (0.71-1.23)
LDI ratio			
Lymphedema arm/control limb			
Hand	1.01 (0.68-1.22)	1.03 (0.68-1.66)	1.06 (0.69-1.59)
Forearm	0.90 (0.44-1.34)	1.01 (0.76-1.38)	1.05 (0.73-1.50)
Upper arm	0.92 (0.78-1.30)	1.15 (0.85-1.37)	1.07 (0.83-1.36)
*LDI=Laser Doppler Imaging			

plexi in the deep dermis, for instance, may contribute appreciably to the LDI signal due to the high blood volume flow, even though they are seemingly located below the average sampling depth. This methodological aspect is an important consideration when interpreting the findings of the present study.

Microvascular Blood Flow and Adipose Tissue

The interrelationship between microvascular blood flow and subcutaneous fat is not completely understood, and, accordingly, data are sometimes difficult to interpret. The pathophysiological state of the lymphedematous arm does not make matters easier. In normal subjects, Larsen (12) found that

the thicker the subcutaneous fat layer, the smaller the blood flow per unit weight (a slow flow rate is considered one condition for lipogenesis and deposition of fat) (13,14). In the lymphedematous arm, previous reports have found increased blood flow (15-17). In our study, however, skin blood flow in the lymphedematous arm was significantly lower than that in the non-edematous control arm preoperatively. There are various possible explanations for these differences. The most obvious one is that both Jacobsson (15,16), using venous occlusion plethysmography, and Svensson (17), using Doppler ultrasound, measured total arm blood flow, whereas methodologically, LDI measures blood flow only to the skin. Jacobsson (15,16), however,

also found increased skin blood flow using isotope clearance methods but these were restricted to observations during body heating.

Thick edematous skin alters the vascular geometry, thereby focusing the LDI measurements on the most superficial capillary level. Lowered blood flow values were recorded from the lymphedematous arm before treatment. A decreased capillary density seems an unlikely explanation for impaired perfusion, as neovascularization in lymphedema has been described (18). An increased number of capillary elements, in combination with condensation of blood vessels in the skin after volume reduction, may explain the higher LDI values from liposuction. According to the Starling hypothesis, removal of trapped macromolecules from the interstitium should increase the transcapillary protein osmotic pressure gradient and thereby promote the absorption of tissue fluid back into the bloodstream. Liposuction increased skin blood flow in the arm with LDI ratios exceeding 1.0. Postoperative reactive hyperemia could be a contributory phenomenon and perhaps explain elevated values at 3 months. It seems, however, less conceivable that this explanation suffices to explain persistently elevated skin blood flow 12 months after liposuction.

In the hand, the preoperative LDI ratio was 1.0, and liposuction induced no significant change. Whereas the explanation for this finding is unclear, our clinical impression is that lymphedema of the hand is generally less prominent than that of the arm, thus necessitating less extensive liposuction. Indeed, 3 patients required no liposuction of the hand. Accordingly, both the effect of lymphedema itself and the effect of liposuction on local skin blood flow may be less evident in the hand.

Cellulitis

Improved superficial skin blood flow remains a plausible explanation for the beneficial effect of liposuction on the inci-

dence of arm cellulitis, a common clinical complication in patients with chronic lymphedema. The point of bacterial entry may be a minor injury to the edematous skin, and impaired skin blood flow may respond inadequately to counteract impending infection. Other circumstances may also provide more favorable environment after liposuction. First, the wearing of a protective compression garment likely renders a patient less prone to injury or other skin lesions. Second, reducing the edema volume by liposuction probably decreases the reservoir of proteinaceous fluid to potentiate bacterial overgrowth, and perhaps, too, already colonized tissue may be removed. Regardless, improved skin blood flow helps protect against the risk of infection.

Skin Blood Flow and Compression

Whereas preoperative LDI measurements were made before instituting compression therapy with garments, postoperative measurements had to be made after removal of such a garment. These differing circumstances led us to study the immediate LDI response upon removal of the garments in 5 additional patients at the 3 month scheduled check-up. Three patients had undergone liposuction whereas 2 were treated with compression only. LDI recordings were made promptly after garment removal and then after 20, 40, and 60 min. The LDI values from the hand did not change, whereas slight increases in LDI values from the forearm and upper arm were noted. These changes were not statistically significant, however. The effect of the compression garment on local skin blood flow thus seems limited. The direction of blood flow changes noted in these 5 patients suggests that increased skin blood flow after liposuction cannot be ascribed to external compression therapy.

CONCLUSIONS

Liposuction of the lymphedematous arm

followed by continuous compression by a garment reduces edema volume almost completely. Both in the forearm and in the upper arm, skin blood flow increases significantly after liposuction with values comparable to that of the healthy arm. Improvements in local skin blood flow may be an important contributing factor to a lowered incidence of cellulitis.

ACKNOWLEDGMENTS

We are indebted to Professor Terence J. Ryan and Doctor Peter S. Mortimer for their fruitful comments on the manuscript, and to occupational therapist Karin Ohlin and physiotherapist Gaby Olsson for skillful assistance.

The clinical work was supported by The Swedish National Board of Health and Welfare (local grants for habilitation and rehabilitation). The scientific evaluation was supported by Malmö University Hospital and the Foundation Against Cancer at Malmö University Hospital.

REFERENCES

1. Kissin, MW, G Querci della Rovere, D Easton, et al: Risk of lymphoedema following the treatment of breast cancer. *Br. J. Surg.* 73 (1986), 580-584.
2. Brorson, H, H Svensson: Complete reduction of lymphoedema of the arm by liposuction after breast cancer. *Scand. J. Plast. Reconstr. Surg. & Hand Surg.* 31 (1997), 137-143.
3. Swedborg, I: Voluminometric estimation of the degree of lymphedema and its therapy by pneumatic compression. *Scand. J. Rehab. Med.* 9 (1977), 131-135.
4. Swedborg, I: Effectiveness of combined methods of physiotherapy for post-mastectomy lymphoedema. *Scand. J. Rehab. Med.* 12 (1980), 77-85.
5. Casley-Smith, JR: Measuring and representing peripheral oedema and its alterations. *Lymphology* 27 (1994), 56-70.
6. Nilsson, GE, T Tenland, PA Öberg: Evaluation of a laser Doppler flowmeter for measurement of tissue blood flow. *IEEE Trans. Biomed. Eng. BME* 27 (1980), 597.
7. Nilsson, GE: Signal processor for laser Doppler tissue flowmeters. *Med. Biol. Eng. Comput.* 22 (1984), 343.
8. Bornmyr, S, M Arner, H Svensson: Laser Doppler imaging of finger skin blood flow in patients after microvascular repair of the ulnar artery at the wrist. *J. Hand Surg.* 19B (1994), 295-300.
9. Ljung, P, S Bornmyr, H Svensson: Wound healing after total elbow replacement in rheumatoid arthritis. Wound complications in 50 cases and laser-Doppler imaging of skin microcirculation. *Acta Orthop. Scand.* 66 (1995), 59-63.
10. Caspary, L, A Creutzig, K Alexander: Biological zero in laser Doppler fluxmetry. *Int. J. Microcir. Clin. Exp.* 7 (1988), 367-371.
11. Jakobsson, A, GE Nilsson: Prediction of sampling depth and photon pathlength in laser Doppler flowmetry. *Med. Biol. Eng. Comput.* 31 (1992), 301-307.
12. Larsen, OA, NA Lassen, F Quaade: Blood flow through human adipose tissue determined with radioactive xenon. *Acta Physiol. Scand.* 66 (1966), 337-345.
13. Vague, J, R Fenasse: Comparative anatomy of adipose. In: *American Handbook of Physiology*. Reynold, AE, GF Cahill, Jr. (Eds.), American Physiology Society, Washington, DC, 1965, pp. 25-35.
14. Smahel, J: Adipose tissue in plastic surgery. *Ann. Plast. Surg.* 16 (1986), 444-453.
15. Jacobsson, S: Blood circulation in lymphoedema of the arm. *Br. J. Plast. Surg.* 20 (1967), 355-358.
16. Jacobsson, S: Studies of the blood circulation in lymphoedematous limbs. *Scand. J. Plast. Reconstr. Surg.* 3(suppl) (1967), 1-81.
17. Svensson, WE, PS Mortimer, E Tohno, et al: Increased arterial inflow demonstrated by laser Doppler ultrasound in arm swelling following breast cancer treatment. *Eur. J. Cancer* 5 (1994), 661-664.
18. Roberts, CC, AW Stanton, J Pullen, et al: Skin microvascular architecture and perfusion studied in human postmastectomy oedema by intravital video-capillaroscopy. *Int. J. Microcir. Clin. Exp.* 14 (1994), 237-234.

Håkan Brorson, M.D.
Department of Plastic and
Reconstructive Surgery
Malmö University Hospital
SE-205 02 Malmö, Sweden