

LYMPHOGRAPHIA

MAGNETIC RESONANCE IMAGING OF PERIPHERAL LYMPHEDEMA

E.M. Insua, J. Viaño, V. Martinez

Instituto Medico Vascular (EMI) and Department of Magnetic Resonance of Clinica, Nuestra Señora Del Rosario (JV,VM), Madrid, Spain

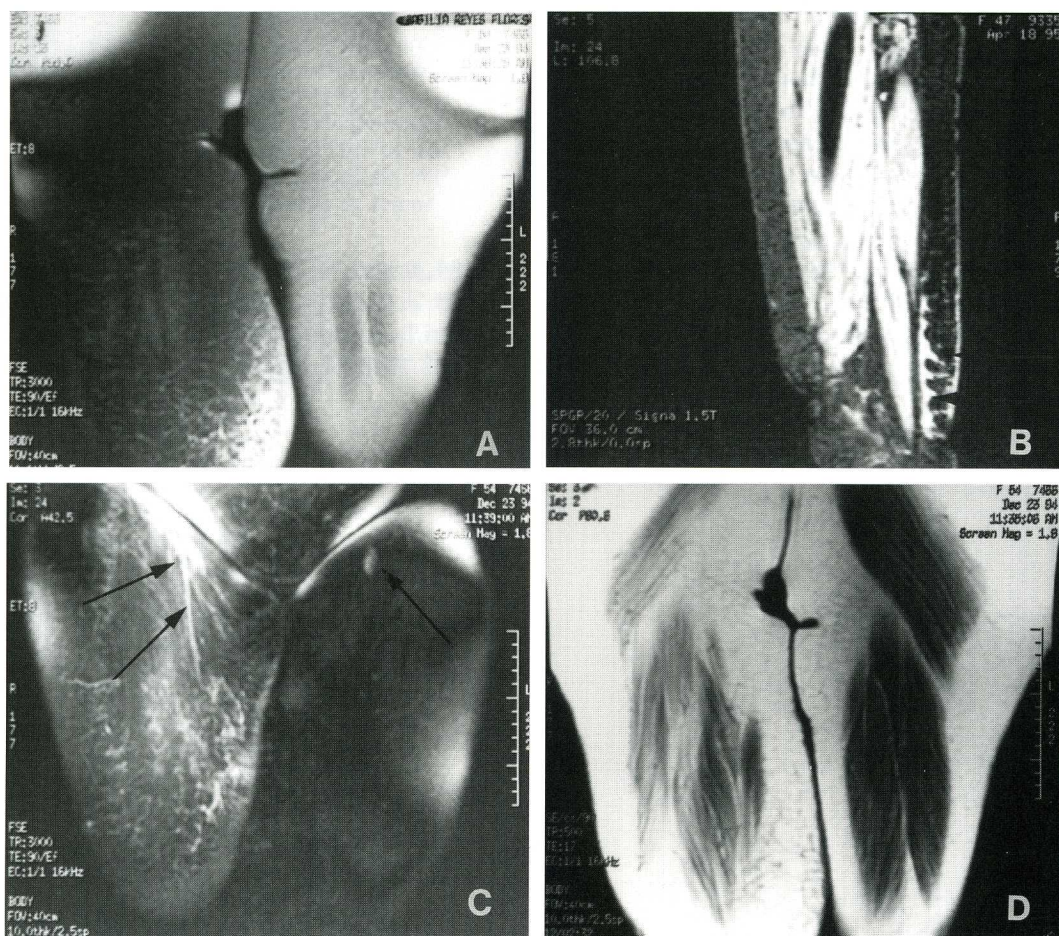


Fig. 1. Magnetic Resonance (MR) Images¹ in Patients with Leg Lymphedema. A. Dilated thigh lymphatics in secondary lymphedema (MR lymphography). B. Subdermal and parafascial fluid (arrows) and fat hypertrophy in secondary lymphedema (spin echo with fat suppression—MR lymphography). C. MR lymphography (3D spin echo with fat suppression) depicting lymphatic collectors and collaterals (arrows, right leg) and inguinal lymph node (arrow, left leg). D. Rare fat infiltration of skeletal muscle in right leg (myopathy with secondary lymphedema).

¹General Electric MR System operating at 1.5 Tesla. Spin echo series with T₁-weighted sequences using repetition time—500msec; echo time—18msec; T₂ fat suppression (phase spin echo) repetition time—3000msec; echo time—95msec. 3D sagittal SPGR; repetition time—45sec; echo time—18msec.

COMMENT

Recently, magnetic resonance imaging has been suggested to depict dermal and subcutaneous abnormalities in patients with peripheral lymphedema (1-3). We studied 10 patients (8 women, 2 men), five with primary and five with secondary lymphedema. Lymphedema was present in the arms in two patients and the legs in seven patients and the genitalia in one patient. Usually the skin was thickened but the findings related more to the length of time that lymphedema was present unless aggravated by irradiation and repeated infection (i.e., cellulitis/lymphangitis). The subcutaneous tissue (epifascial compartment) was uniformly enlarged and contained fluid, a finding notably absent in "lipedema" (obesity). Typically a trabecular or honeycombed pattern was found (*Fig. 1A*). T₂-weighted images corresponded primarily to liquid but using spin echo 3D with fat suppression made it even easier to distinguish fat from fluid and highlighted lymphatic collectors and regional lymph nodes (*Figs.*

1B,1C). Fibrosis of the subcutaneous tissue is commonly seen with repeated cellulitis or irradiation. The subfascial compartment (skeletal muscle) was typically uninvolved although occasionally muscle was infiltrated by adipose tissue (*Fig. 1D*) as with the Parke-Weber angiodysplasia syndrome.

REFERENCES

1. Case, TC, CL Witte, MH Witte, et al: Magnetic resonance imaging in human lymphedema: Comparison with lymphangiography. *Magnetic Resonance Imaging* 10 (1992), 549.
2. Duwells, S, KD Hagspiel, J Zuber, et al: Swollen lower extremity: Role of MR imaging. *Radiology* 184 (1992), 227.
3. Haaverstad, R, G Nilsen, PA Rinck, et al: The use of MRI in the diagnosis of chronic lymphedema of the lower extremity. *Int'l. Angiol.* 41 (1989), 143.

E.M. Insua, M.D. c/o
Prof. J.A. Jiménez Cossío
Avenida de San Luis, 93-1.º H
28033 Madrid, Spain