

MANAGEMENT OF THORACIC DUCT COMPLEX LESIONS (CHYLOTHORAX): EXPERIENCE IN 16 PATIENTS

A. Cariati, M. Taviani, G. Pescio, S. Cesaro, P. Cariati, F. Conti, E. Cariati

Institute of Anatomic Surgery, Specialization School of Thoracic Surgery, University of Genoa, Genoa, Italy

ABSTRACT

From our experience in 16 patients with persistent chylothorax from fistulas of the thoracic duct or its tributaries, we conclude that no standard treatment is uniformly successful and multimodality therapy should be considered. In selected patients, an anastomosis between ectatic lymphatics or hyperplastic lymph nodes and an adjacent vein may be attempted.

Chylothorax from "leakage" of the thoracic duct or its tributaries is rare. Rupture of the thoracic duct superior to the sixth thoracic vertebrae generally results in a left-sided chylothorax; below that level, injury usually results in a right-sided chylothorax. The etiology is heterogeneous and includes blunt trauma, penetrating wounds (1), iatrogenic operative injury and lymphatic obstructions due to congenital abnormalities, inflammatory processes or neoplasms. Based on our experience in 16 patients with persistent chylothorax from thoracic duct complex lesions, we review the available treatment options.

CASE MATERIAL

Sixteen patients with lesions of thoracic duct or its tributaries and persistent chylothorax treated at the Institute of Thoracic Surgery of Genoa (1973-1986) and at the Institute of Anatomic Surgery (1986-1993)

are examined. Of the 16 patients (12 men, 4 women), 5 had post-traumatic chylothorax, 4 had spontaneous acquired chylothorax (3 with cervico-mediastinal tumors and 1 idiopathic associated with high fever, steatorrhea and ascites); 6 had iatrogenic injury (post cardiovascular, esophageal, or pleuro-pulmonary operations) and 1 had chylothorax associated with lymphangiomyomatosis (Table 1).

Signs and symptoms included hypoproteinemia (13 patients), chronic anemia (13 patients), weight loss (12 patients), steatorrhea or diarrhea (10 patients), ascites (9 patients), and dyspnea (6 patients) (Table 2). Each patient underwent conventional lymphography and had serial chest radiographs.

After diagnosis of chylothorax was confirmed, total parenteral nutrition or a restricted fat diet were begun and either multiple thoracenteses or insertion of a thoracostomy tube for pleural drainage was performed. This non-operative treatment was continued for 2-3 weeks with the anticipation that the lymphatic fistula would close spontaneously. In 6 patients (2 after iatrogenic injury and 4 with post-traumatic chylothorax), the leak indeed closed spontaneously. After 3 weeks of unsuccessful nonoperative therapy with potential nutritional depletion, infection and dehydration we opted for operative correction. In 4 patients with iatrogenic injury and chylothorax, we ligated the thoracic duct on the

TABLE 1
Etiology of Chylothorax (16 Patients)

Cause	# Patients	(%)
Iatrogenic (Surgical)	6	(38)
Traumatic	5	(31)
Tumor	3	(19)
Idiopathic (? infectious)	1	(6)
Lymphangiomyomatosis	1	(6)

side of the leakage with symptomatic resolution of chylothorax. Intrathoracic lymphatic identification was aided by ingestion of a fatty meal 4-5 hours before thoracotomy. In one patient, a Denver pleuro-peritoneal shunt was inserted but the patient developed an intrathoracic empyema and died. In 3 patients with chylothorax and persistent neoplasia despite chemotherapy, a talc pleurodesis successfully obliterated the pleural space and resolved the chylous pleural effusion.

In one patient with traumatic chylothorax, we inserted an end-to-side thoracic duct anastomoses with permanent resolution of signs and symptoms. In another patient, a 31 year old woman with lymphangiomyomatosis, three lymphatic-venous shunts were constructed between the thoracic duct or its major tributaries and the adjacent azygos and intercostal veins using magnification lenses (5 diopter) and 7-0 nylon. Although the chylothorax disappeared, she died six months later from restrictive lung disease while awaiting a pulmonary transplant. In another patient, a 14 year old boy with idiopathic chylothorax associated with high fever and steatorrhea and protein-losing enteropathy, we attempted lymphatic-venous anastomoses using a tributary of the thoracic duct to an intercostal vein at the first operation (*Fig. 1*) and using

TABLE 2
Presenting Signs and Symptoms

Signs and Symptoms	# Patients	(%)
Hypoproteinemia	13	(81)
Chronic Anemia	13	(81)
Weight Loss	12	(75)
Steatorrhea/Diarrhea	10	(62)
Ascites	9	(56)
Dyspnea	6	(38)

hyperplastic lymph nodes of the porta hepatis to a lumbar vein at the second operation (*Fig. 2*). Clinical improvement however was transient and recurrence six months later of chylous ascites led to insertion of a peritoneal-jugular shunt (LeVein).

DISCUSSION

Chylothorax is uncommon and treatment cannot be standardized because of innumerable variables including age of the patient, etiology, magnitude of the fistula output and its persistence. Non-operative therapy is recommended for 2-3 weeks which includes oral ingestion of small and medium-chain triglycerides (which are absorbed primarily by the portal venous system), and/or parenteral hyperalimentation, decompression of the pleural space by multiple thoracenteses or closed thoracostomy with suction drainage.

Ligation of the thoracic duct, first performed by Lampson (2), is recommended in post-traumatic or post-iatrogenic chylothorax when the daily output of chyle exceeds 1,000 ml (3) or 1500 ml (4) or when leakage persists beyond 2-3 weeks (3,4). With persistent post-iatrogenic chylothorax, an external (5) or internal (6) pleuro-peritoneal shunt or thoracoscopic application of "fibrin glue" (7) may be useful. Pleurodesis is clearly worth-

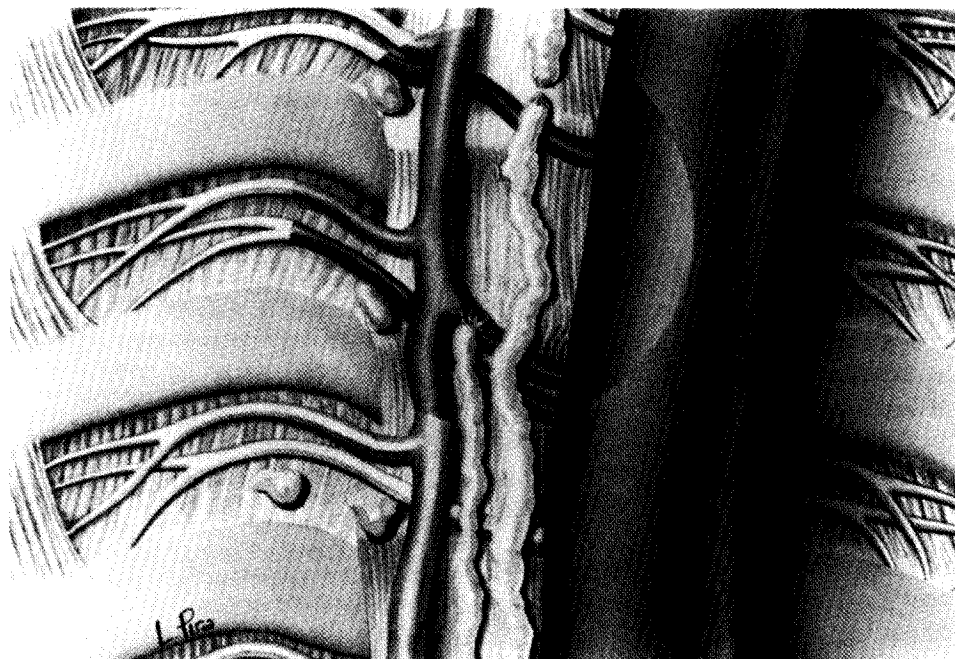


Fig. 1. Schematic diagram of lymphatic-venous anastomosis between a collateral of the thoracic duct and an adjacent intercostal vein in a 14 year old boy with idiopathic chylothorax, steatorrhea, chylous ascites, and protein-losing enteropathy.

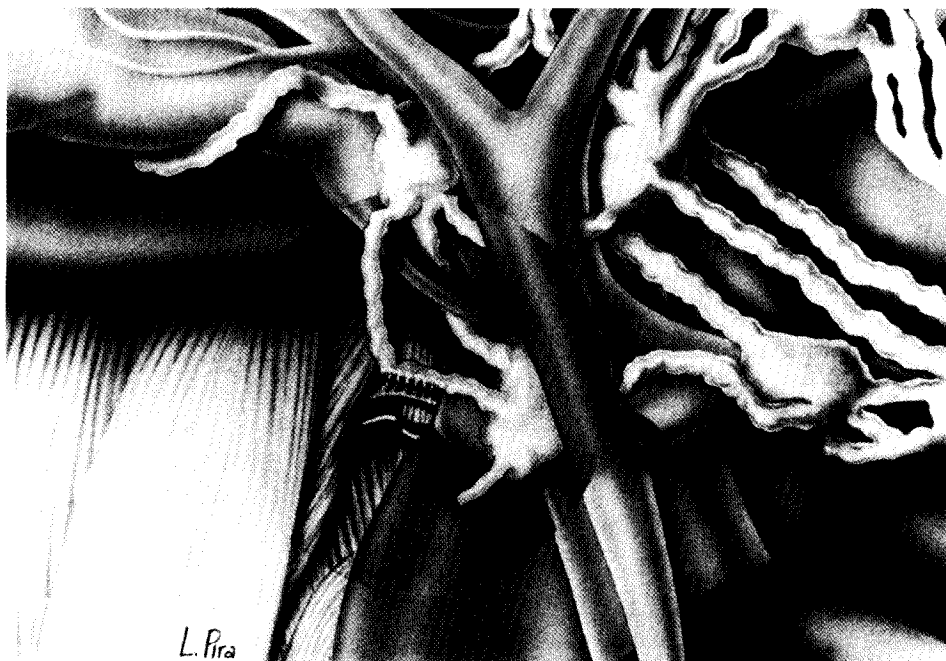


Fig. 2. Schematic diagram of a lymphatic-venous anastomosis done in a 14 year old boy as described in Figure Legend 1 between hyperplastic lymphatics and lymph nodes of the porta hepatis and an adjacent lumbar vein.

while in persistent chylothorax especially with intrathoracic malignancy (8). Thoracic duct ligation and tumor excision has also been suggested for the rare lymphangioma of the thoracic duct (9).

Lymphatic-venous anastomoses have also been recommended to treat a wide variety of lymphatic dysplastic syndromes (10-14). Demonstration of long-term patency of these shunts, however, is rarely documented. We, too, have demonstrated the feasibility of performing these anastomoses with chylothorax and also suggest the possibility of using hyperplastic lymph nodes as the anatomic conduit. Whereas we have observed temporary improvement in the signs and symptoms of chylothorax after these lymphatic bypass operations, the underlying disease either progressed (e.g., lymphangio-myomatosis) or the patient relapsed (recurrent chylous ascites); moreover, thus far, long-term patency of the shunt procedure has not been verified. Accordingly, despite physiologic soundness in diverting visceral lymph more directly into the bloodstream and technical feasibility by microsurgery in doing the anastomosis, at this time we recommend that these procedures should still be considered as investigational.

REFERENCES

1. Ross, JK: A review of the surgery of the thoracic duct. *Thorax*. 16 (1967), 12-21.
2. Lampson, RS: Traumatic chylothorax: Review of literature and report of case treated by mediastinal ligation of the thoracic duct. *J. Thor. Surg.* 17 (1948), 778.
3. Selle, JC, WH Suyder, JT Schneiberg: Chylothorax: Indication for surgery. *Ann. Surg.* 177 (1971), 245-249.
4. Taba, L, HV Debrina, R Bower, et al: Chylothorax review. *Crit. Care Med.* 13 (1985), 49-52.
5. Cummings, S, D Wyatt, JW Baker, et al: Successful treatment of postoperative chylothorax using an external pleuroperitoneal shunt. *Ann. Thorac. Surg.* 54 (1992), 276-278.
6. Murphy, MC, BM Newman, BM Rodgers: Pleuroperitoneal shunts in the management of persistent chylothorax. *Ann. Thorac. Surg.* 48 (1989), 195-200.
7. Inderbitzi, R, T Krebs, BM Stirnemann, et al.: Treatment of postoperative chylothorax by fibrin glue application under thorascopic view with use of local anesthesia. *J. Thorac. Cardiovasc. Surg.* 104, (1992), 209-210.
8. Adler, R, L Levinsky: Persistent chylothorax: Treatment by talc pleurodesis. *J. Thorac. Cardiovasc. Surg.* 6:76 (1978), 859-864.
9. Vecchioni, R, C Cordiano, D D'Amico: *Il Chilotorace*. Piccin (Ed.), Padova, 1973.
10. Hodge, GB, H Bridges: Surgical management of thoracic duct injuries: Experimental study with clinical application. *Surg.* 24 (1948), 805.
11. Degni, M, V Lemas-Torres, A Degaday, et al: Lymphovenous and lympho-esophageal shunts in the surgical treatment of portal hypertension. *Rev. Bras. Chir. Cardiov.* 1 (1965), 309.
12. Harrison, E: On treatment of wounds of thoracic duct. *Brit. J. Surg.* 4 (1916), 304.
13. Gruwez AJ, C Lacquet, G Cardoen, et al: Considerations sur le chylothorax. *Acta Clin. Belgie* 1 (1967), 64.
14. Gruwez, J, G Cardoen, C Dive et al: Chylothorax. In: *Progress in Lymphology I*. Rüttimann, A (ed.), George Thieme, Stuttgart, 1967, p 30.

A. Cariati, M.D.
Institute of Anatomic Surgery
Specialization School of Thoracic Surgery
Director Prof. E. Cariati
Via Benedetto XV, 10
CAP 16132 Genoa, ITALY