

STEWART-TREVES ANGIOSARCOMA OF ARM AND IPSILATERAL BREAST IN POST-TRAUMATIC LYMPHEDEMA

A. Trattner, O. Shamai-Lubovitz, R. Segal, A. Zelikovski

Departments of Dermatology (AT,OS-L,RS) and Vascular Surgery (AZ), Beilinson Medical Center, Petah Tiqva and Sackler Faculty of Medicine. Tel Aviv University, Tel Aviv, Israel

ABSTRACT

An elderly woman is presented who developed a rapidly fatal angiosarcoma of the upper extremity and ipsilateral breast in the setting of longstanding arm lymphedema following a childhood accident.

Stewart-Treves angiosarcoma (S-T) is a rare malignant tumor of the vascular endothelium arising in an area of chronic lymphedema. First described as post-mastectomy lymphangiosarcoma in 1948 (1), S-T typically develops in the edematous ipsilateral arm more than five years after radical mastectomy in approximately 0.45% of surviving patients (2). An angiosarcoma may also arise in a chronic and severely edematous extremity usually of congenital origin without a preceding tumor (3-5), rarely in idiopathic lymphedema of delayed onset (6,7), and even more rarely in chronic lymphedema secondary to filariasis (8,9).

We now report an elderly woman who developed angiosarcoma of the upper extremity and ipsilateral breast in the setting of severe arm lymphedema after childhood trauma.

CASE REPORT

A 72-year-old woman had chronic edema of the right upper extremity since childhood

after her arm sustained severe soft tissue damage after trampled upon by a horse. Three years earlier, she had noted enlargement of the right breast, but mammography six months before was unremarkable. Aggravation of the arm edema and the emergence of soft bluish-violaceous plaques in the skin of the swollen arm without nodules or ulceration (*Fig. 1*) prompted reevaluation. Physical examination revealed diffuse stiffening of the right breast but without masses or lymphadenopathy.

Histology of a biopsy specimen taken from the right forearm skin showed vascular structures lined with proliferating endothelial cells. Atypical endothelial cells were present in clusters and were infiltrating the subcutis (*Fig. 2*). Cytological examination of a fine needle aspirate from the breast also disclosed clusters of endothelial cells several with atypical nuclei and of bizarre form. Immunohistochemical stains for keratin and CEA were negative and for vimentin Factor VIII-von Willebrand and CD3 were positive. The findings were compatible with angiosarcoma.

A right upper extremity plain radiogram showed edema of the soft tissues but no bone involvement. Computer tomography of the chest showed large lumps of soft tissue without distinctive borders, arising from the right axilla and along the right chest. Bone and liver scans were unremarkable.

Despite a course of chemotherapy, she died shortly thereafter.

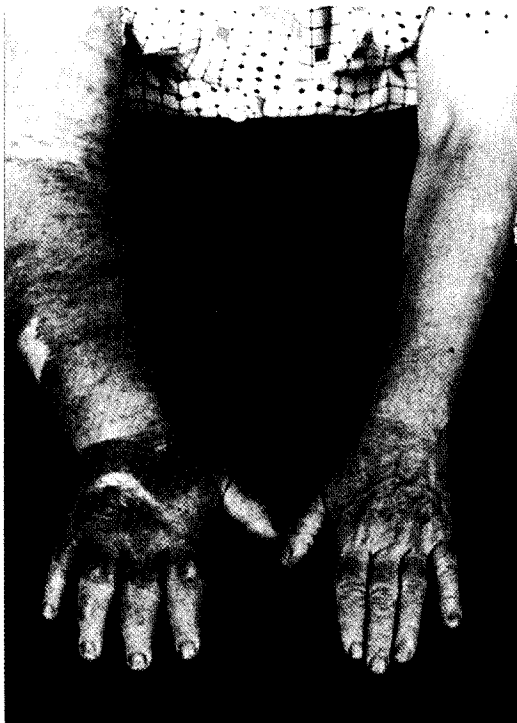

Fig. 1. 72-year-old woman with angiosarcoma of the right arm which developed in a chronically lymphedematous extremity related to childhood trauma. Numerous plaques (dark blue) are visible.

COMMENT

In the original Stewart-Treves syndrome, the mean patient age at appearance of the angiosarcoma was 62 years, and the mean interval between mastectomy and the appearance of the tumor was 10.5 years (2). Two male patients with angiosarcoma have been reported after mastectomy (10). In most patients, the clinical course and autopsy findings have documented that the breast carcinoma was eradicated. Moreover, these patients have had less frequent involvement of the axillary nodes with metastatic breast cancer (10).

Although most patients have been associated with arm lymphedema after treatment (operation and/or irradiation) for breast cancer, several reports of angiosarcomas have now been described in other lymphedemas

including the legs. Most commonly the lymphedema is of congenital origin (e.g., Milroy's disease). Rare patients with angiosarcoma associated with idiopathic lymphedema of delayed onset have occurred (6,7) and even more rarely has angiosarcoma occurred with lymphedema from filariasis (8,9). Isolated reports include patients with Maffucci's syndrome (11), chronic leg lymphedema after dissection of the inguinal lymph nodes for treatment of malignant melanoma (12), longstanding lymphedema after burn injury in childhood (13), and in a pre-existing non-irradiated lymphangioma (14).

To our knowledge, our report is the first example of an angiosarcoma arising in an arm with longstanding lymphedema caused by childhood trauma.

REFERENCES

1. Stewart, FW, N Treves: Lymphangiosarcoma in postmastectomy lymphedema. A report of six cases in elephantiasis chirurgica. *Cancer* 1 (1948), 64-81.
2. Herrman, JB: Lymphangiosarcoma of the chronically edematous extremity. *Surg. Gynecol. Obstet.* 121 (1965), 1107-1115.
3. Merrick, A, RA Erlandson, SJ Hajdu: Lymphangiosarcoma of a congenitally lymphedematous arm. *Arch. Pathol.* 91 (1971), 365-371.
4. Dubin, HV, EP Creehan, JT Headington: Lymphangiosarcoma and congenital lymphedema of the extremity. *Arch. Dermatol.* 110 (1974), 608-614.
5. Laskas, JJ Jr, WB Shelley, MG Wood: Lymphangiosarcoma arising in congenital lymphedema. *Arch. Dermatol.* 111 (1975), 86-89.
6. Baes, H: Angiosarcoma in a chronic lymphedematous leg. *Dermatologica* 134 (1967), 331-336.
7. Chen, KTK, EF Gilbert: Angiosarcoma complicating generalized lymphangiectasia. *Arch. Pathol.* 103 (1979), 86-88.
8. Sordillo, EM, PP Sordillo, SL Hajdu, et al: Lymphangiosarcoma after filarial infection. *J. Dermatol. Surg. Oncol.* 7 (1981), 235-239.
9. Muller, R, SL Hajdu, MF Brennan: Lymphangiosarcoma associated with chronic filarial lymphedema. *Cancer* 59 (1987), 179-183.




Fig. 2. Photomicrographs of biopsy specimens of a plaque on the right forearm. Multiple vascular spaces lined with proliferating clusters of endothelial cells are seen extending into the subcutaneous tissue. (hematoxylin and eosin, A x35; B x250)

10. Oettle, AG, PJP Van Blerk: Postmastectomy lymphostatic endothelioma of Stewart and Treves in a male. *Br. J. Surg.* 50 (1963), 736-743.
11. Kerr, HD, JC Keep, S Chiu: Lymphangiosarcoma associated with lymphedema in a man with Maffucci's syndrome. *South Med. J.* 84 (1991), 1039-1041.
12. Ronan, SG, HA Briele, JR Manaligod: Lymphangiosarcoma in chronic lymphedema that followed dissection of the groin in surgical management of a malignant melanoma. *Am. J. Dermatopathol.* 6 (1984), 245-251.
13. Deutschmann, W, MG Smola, E Scharnagl, et al: Stewart-Treves syndrom und lymphangiosarkom. *Chirurg.* 59 (1988), 605-609.
14. Moss, AL, NB Ibrahim: Lymphangiosarcoma of the hand arising in a pre-existing non-irradiated lymphangioma. *J. Hand Surg.* 10 (1985), 239-242.

A. Trattner, M.D.
Department of Dermatology
Beilinson Medical Center
Petah Tiqva 49 100
Israel
Phone: 972-3-937-7160