

MORPHO-PHYSIOLOGICAL FUNCTION AND ROLE OF OMENTAL MILKY SPOTS AS OMENTUM-ASSOCIATED LYMPHOID TISSUE (OALT) IN THE PERITONEAL CAVITY

M. Shimotsuma, J.W. Shields, M.W. Simpson-Morgan, A. Sakuyama,
M. Shirasu, A. Hagiwara, T. Takahashi

First Department of Surgery, Kyoto Prefectural University of Medicine, Kyoto, Japan (MS,AS,MS, AH,TT), Hematology and Medicine, Santa Barbara Medical Foundation Clinic, Santa Barbara, California, USA (JWS), Developmental Physiology Group, John Curtin School of Medical Research, Australian National University, Canberra, Australia (MW-SM)

ABSTRACT

The morpho-physiological function and role of milky spots in the greater omentum are reviewed. These milky spots are composed of cellular aggregations of mesenchymal cells, mainly macrophages and lymphocytes, surrounding capillary convolutions termed omental glomeruli. Initial lymphatics of the omentum begin at the milky spots and drain into lymph collectors. The lymphatic capillaries in the omental milky spots take part in the absorption of various substances from the peritoneal cavity.

Omental milky spots probably act as the first line of defense in the peritoneal cavity and therefore are immunologically important. In human infants, most of the cells in these milky spots are macrophages (49%); less common are B lymphocytes (29%) and T lymphocytes (12%). Whereas macrophages form clusters near the peritoneal surface of the milky spots and are oriented toward the peritoneal cavity for migration, clusters of B and T lymphocytes are typically found in periarteriolar locations within the milky spots. This cell zonation facilitates phagocytosis and processing of circulating antigens and foreign bodies which emanate from the peritoneal cavity. During inflammation, the number and size of omental

milky spots dramatically increase, and some develop germinal centers within the lymphatic follicles and produce antibodies. During intraperitoneal immunotherapy, the omental milky spots and their cellular elements may be activated by intraperitoneal administration of biological response modifiers, and thereby represent an important immunoregulatory system for the peritoneal cavity.

Omental milky spots are also closely linked to the dissemination of cancer cells. Thus, intraperitoneally inoculated experimental tumor cells selectively invade the milky spots and proliferate there to form tumor nodules. This occurrence is relevant to clinical practice where nodular metastases to the omentum are common.

Omental milky spots are analogous to regional lymph nodes and as such are the omentum-associated lymphoid tissues and participate in intraperitoneal immune reactions.

The greater omentum has been called the "policeman of the abdomen" because of its protective role within the peritoneal cavity (1). This "policeman" has numerous tiny white lymphoid nodules called milky spots. Since the latter half of the 19th century, such milky spots have been described in the omentum and

pleura (2). In Fawcett's book of histology (3), the milky spots are described as follows: "In certain areas, the macrophages and other free cells accumulate in especially dense masses. Such macroscopically visible areas are often arranged along the blood vessels as round or oval patches called milky spots. These are sometimes found in the thin net like part of the omentum. They are especially characteristic of the omentum of the rabbit." Since Ranvier (4) named them "taches laiteuses" in 1874, many workers have investigated the structural organization and functional significance of the milky spots in the various animals: mice (5-45), rats (5,6,16,18,21,33,34, 46-68), guinea-pigs (5,12,21,50,69), rabbits (5-7,13,50,69,70), dogs (6,65,71,72), pigs (5,73), cattle, chickens, frogs (5), ground squirrels, cats, bats, moles (6), sheep and goats (74). In humans, however, milky spots have not been ordinarily described as integral portions of the lymphatic apparatus, and their clinical evaluation has received little attention. In the human omentum, it is difficult to identify the milky spots, because they are very small compared with lymph nodes and are usually embedded in adipose tissue, particularly in older subjects. This paper reviews the morpho-physiological function and significance of the milky spots as omentum-associated lymphoid tissue (OALT) in the peritoneal cavity.

LOCATION OF MILKY SPOTS

In mice, milky spots are located not only in the greater omentum and pleura but also in special areas: uterine fringe (9), parietal peritoneum over the pancreas (32), gastro-splenic ligament and mesenteric root (28).

Seifert (75) reported on the milky spots in the human greater omentum in 1921. In 1928 Kampmeier (76) showed similar plaques of macrophages in the mediastinal pleura behind the heart of a human newborn baby. These were called Kampmeier's foci (Fig. 1). Highly vascularized milky spots on the chest wall were also reported in human newborn (77).

In the human greater omentum, we

studied vascularized milky spots (78). In humans, the number of milky spots per unit area is the greatest in infancy, and gradually decreases with age (Fig. 2). In infancy, the average number of milky spots per square centimeter of greater omentum is from 30 to 40. As surface area of greater omentum increases with body growth, the number becomes lower: 19.6 at 1 year of age, 8.9 at 3 years of age. In children and adolescence, the number of milky spots decreases to between 3.5 and 5.3 per cm^2 . In adults, the average number is approximately 2 per cm^2 .

VASCULAR SYSTEM OF MILKY SPOTS

Omental milky spots consist of mesenchymal cells surrounding blood vessels (Fig. 3). The blood supply is received from the

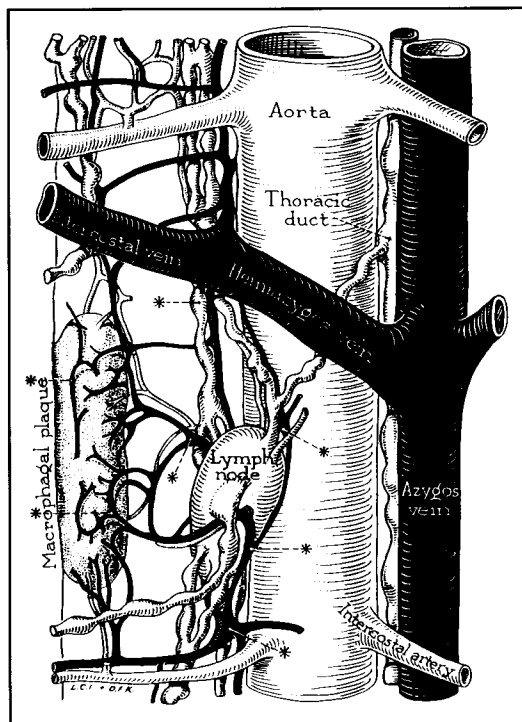


Fig. 1. Macrophagal plaque called Kampmeier's foci in the mediastinal pleura of a newborn baby (6,76).

LYMPHATIC SYSTEM OF MILKY SPOTS

Casparis (82) and later Simer (83,84) clearly demonstrated the lymphatics of the omentum. Omental lymph channels generally associate with arterial blood vessels and join the collecting lymph vessels which lie near the margins of the fat strips. Foreign particles introduced into the peritoneal cavity and erythrocytes produced by intraperitoneal hemorrhage are partly absorbed into the lymphatic vessels in the omentum. However, the role of the omentum in the removal of materials appears small in comparison with that in the diaphragm (85).

Webb and Simer (65) described the relation of lymph vessels to omental milky spots. In rats and guinea pigs, a plexiform arrangement of lymph vessels pervades the milky spots. On the other hand, in dogs and rabbits, the lymph vessels are larger, less plexiform, and distend in some areas. The lymph from the milky spots may drain into the cisterna chyli and thence to the thoracic duct.

In the rabbit omentum, blind endothelial sacculations of terminal lymphatics (30-50 μ m wide) are present within milky spots. These drain into collecting channels (86). Electron microscopic examination suggests that the initial lymphatics in the milky spots open into the peritoneal cavity because the endothelial cells of lymphatics mesh with the mesothelial cells within connective tissue of a characteristic structure, similar to that of the macula cribiformis in the diaphragm described earlier by Kihara (87).

In human milky spots, Borisov (88) showed lymphatic capillaries with blind beginnings demonstrated by means of Georta blue dye injection. In the larger milky spots, the diameter of dilated lymphatic capillaries can reach 150 μ m or more. The lymphatic capillaries of the milky spots, which are often superficial in position and close to the mesothelial cells, emerge from the milky spots and empty into the efferent lymphatic vessels. Borisov (88) proposed that lymphatic capillaries in the milky spots of the human greater

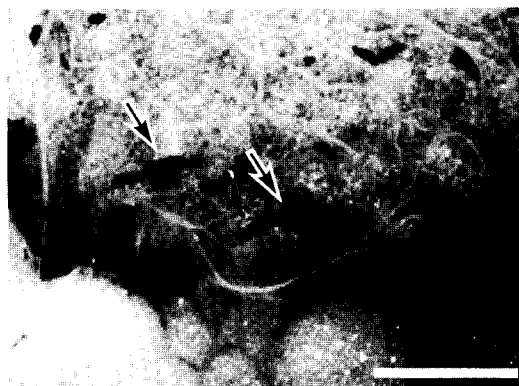


Fig. 5. Black stained milky spots (arrows) in the human greater omentum. Many macrophages in the milky spots contain numerous carbon particles within their cytoplasm. Bar=1mm.

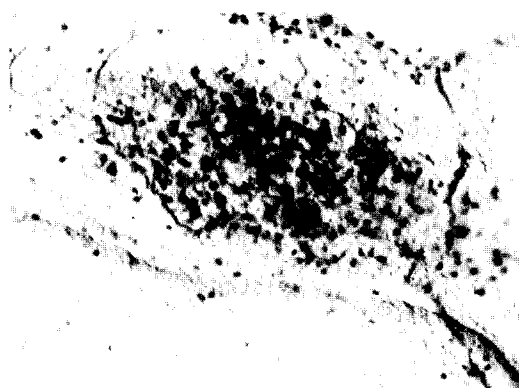


Fig. 6. Macrophages in the human omental milky spot immunohistochemically detected by Leu-M5 (CD11c) monoclonal antibody (interference contact photomicrograph).

omentum may take part in the absorption of various substances from the peritoneal cavity.

MILKY SPOT MACROPHAGES AND PERITONEAL MACROPHAGES

Macrophages, the most numerous cellular components of milky spots (30-48%) (63,89) can be recognized by their phagocytic activity. Mixer (6) injected India ink or trypan blue into the rat thoracic cavity and designated the milky spots in the pleura as "macrophagal foci" owing to the obvious presence of injected India ink or trypan blue.

In rats, the milky spots of the greater omentum can be seen by the naked eye as black spots as early as thirty minutes after injecting a carbon suspension of particles less than 20nm in size (78,90). In a human, the omental milky spots turned black when a carbon suspension was inadvertently injected into the peritoneal cavity (91) (*Fig. 5*). The day before gastric resection in a 41 year old man with a tiny gastric tumor during gastroscopy, some of this carbon suspension leaked into the peritoneal cavity. Because of the time of operation his greater omentum was dotted with black spots. Histological examination of the black spots showed that many macrophages in the milky spots contained numerous carbon particles within their cytoplasm.

In infants, under non-inflammatory conditions, the mean number of cells per milky spot is 570 ± 33 (mean \pm SD), of which $47.5 \pm 7.5\%$ are immunohistochemically stained by the macrophage specific Leu-M5 (CD11c) monoclonal antibody (89) (*Fig. 6, Table 1*). On the surface of milky spots, the mesothelial cells which line the peritoneal cavity are often replaced by macrophages (10,14-16,18,92). In some instances, these macrophages form two or three layers and orient toward the peritoneal cavity for trapping or permitting the entrance of foreign particles. Electron microscopic studies confirm the occurrence of openings between the covering cells of milky spots which reach into the depths of the milky spots, providing possible pathways for the entrance or exit of cells (10,18,33,37,44,58). In mice, Cranshaw and Leak (44) using both scanning and transmission electron microscopy, demonstrated that areas perceived as opening on the mesothelial surface represent gaps between mesothelial cells which expose the underlying connective tissue matrix. The absence of a basement membrane between the mesothelial cell covering of the milky spots and the underlying connective fibers (10,14,15, 18,33,44) and discontinuous mesothelial covering (10,14-16,92) are pertinent. These structural peculiarities of opening provide suitable environment for the cells within the

milky spots to migrate from the interstitial spaces into the peritoneal cavity, or vice versa, without having to penetrate a definitive impermeable barrier. There have been many studies on the origin of peritoneal macrophages and their relation to the milky spots (21,33-35,52,68). Dames and de Bakker (35) described two different types of peritoneal macrophages on the basis of their origin. Under inflammatory conditions, most peritoneal macrophages derive from monocytes produced in the bone marrow. However, in the normal state, peritoneal resident macrophages derive from locally proliferating progenitor cells in the milky spots which themselves arise from specific stem cells in the bone marrow. On the other hand, Beelen et al (33,34) divided the milky spot macrophages into three types (exudate macrophages [monocytes], exudate-resident macrophages and resident macrophages) on the basis of their different peroxidase activity pattern. They studied their localization and the kinetics in the milky spots. During the normal steady state, the majority (>90%) of macrophages are resident macrophages which localize mostly peripherally in the milky spots. Exudate macrophages or monocytes increase their numbers and develop into exudate-resident and resident macrophages, and these cells also contribute to the different phases of development of the free peritoneal macrophages. Moreover, under the inflammatory conditions, even promonocytes are localized perivascularly in the milky spots, which locally serve as a pool of monocytes and macrophages. They suggested that at least some of the free peritoneal macrophages are derived from blood-borne mononuclear phagocytes in the milky spots, both in normal state and during inflammation.

MILKY SPOTS AND THE LOCAL IMMUNE RESPONSE

In 1874, Ranvier (4) considered the omentum in a sense as a large flattened-out lymph node, the lymph sinus of which is represented by the peritoneal cavity. Under

TABLE 1
Cellular Subsets in the Human Omental Milky Spots*

Total number of cells per one milky spot	570 ± 33
Percentage of cellular subsets	
Macrophages	47.5 ± 7.5%
B lymphocytes	29.1 ± 5.2%
T lymphocytes	11.7 ± 2.4%
Mast cells	6.1 ± 2.6%
*8 month-old infants (males and females) without intraperitoneal inflammatory disease.	

inflammatory conditions, milky spots increase in their number and size, and act as the first line of defense in the peritoneal cavity (*Fig. 2*) (33,34,39,62,78).

Omental milky spots are immunologically important in the peritoneal cavity. We consider them to be highly analogous to regional lymph nodes (91,92). In humans, the cellular composition of the milky spots in infants show that the majority of cells are macrophages (47.5%). The second major cell component represents B lymphocytes (29.1%) and T lymphocytes (11.7%) (89) (*Table 1*). Mast cells are rare (6.1%). Since inflammation appeared absent in our material, our findings could be regarded as representative cell numbers in normal human milky spots. Macrophages covering the milky spots which face the peritoneal cavity trap and digest the circulating antigens and foreign bodies which are introduced into the peritoneal cavity. The macrophages may transfer information to lymphocytes in the central part of the milky spots (91,92). Thus, functional cellular zonation of omental milky spots corresponds to the structural relation between macrophages lining the lymph sinus wall and lymphocytes in the germinal center of the lymph node. In lymph nodes, afferent lymph vessels lead to a dome shaped network of lymph sinus around individual follicles. These

continue directly into a dense medullary sinusoidal network leading in turn to efferent lymph vessels which leave the node at the hilus. From a clinical standpoint of view, the omental milky spots may function to absorb antigenic proteins or bacteria which are introduced into the peritoneal cavity during gut inflammation, perforation or at operation. The omental lymphatics which emanate from milky spots may correspond to the efferent lymph vessels of the lymph nodes.

Dux et al (40) have analyzed the lymphoid cell composition of mouse milky spots before and after intraperitoneal immunization with sheep erythrocytes. Mouse milky spots contain surface immunoglobulin-positive B lymphocytes, and T cells of the helper and cytotoxic phenotype. After secondary antigen challenge the number of lymphocytes increase. The B and T cells segregate into distinct areas; the B cell zone is peripheral resembling primary follicles of lymph node and the T cells are centrally located resembling the lymph node paracortex. Therefore, Dux et al concluded that milky spots act as a peripheral lymphoid organ in the peritoneal cavity.

It has long been considered that the omentum takes part in the humoral defense of the host response to intraperitoneal "vaccination" (13,20,93). Production of antibodies in the milky spots may contribute

to the humoral immunity of the omentum. Hajdu et al (20) reported that the majority of the antibody-containing cells are localized predominantly in milky spots after a booster injections of antigen. Other studies by Mandache et al (62) have shown the appearance of lymphatic follicles, some with germinal centers after intraperitoneal stimulation using sodium thioglycolate, China ink and typhoid vaccine. Therefore, they proposed that omental milky spots are subsidiary secondary lymphoid organs.

MILKY SPOTS AND INTRAPERITONEAL CANCER DISSEMINATION

Gastrointestinal and ovarian cancer frequently metastasize to the greater omentum, more or less like experimental tumor cells spread as metastatic nodules in the omentum.

Dux (16) reported that milky spots become hypertrophic and congested soon after intraperitoneal inoculation of Ehrlich ascites tumor in rats and mice. As the tumor cells aggregate around the milky spots, plasma cells accumulate in the central areas of the milky spots. Finally, after the rejection of tumor cells, the milky spots are replaced by granulation tissue. He suggested that the milky spots are the target for the formation of the small omental nodules in the advanced stage of Ehrlich ascites tumors. Skurzak and Dux (53) also demonstrated the immunological response of rat milky spots inoculated with Ehrlich ascites tumor cells by immunofluorescence. The number of gammaglobulin producing cells in milky spots increases from the second day after tumor transplantation and reaches 60-70% after 9 days.

Green and Williams (57) observed the WP1 tumor cell behavior in the rat omentum. Eight hours after intraperitoneal injection of WP1 tumor cells, scattered tumor cells were attached to the surface of milky spots. After 24 hr after tumor injection, the surfaces of the milky spots compromised a mass of tumor cells. The mesothelium covering them was disrupted by an inflammatory response and

openings were created in their surface, whereas the mesothelium overlying surrounding adipose tissues appeared intact. After 24 hr, tumor cells conspicuously increased with a progressive inflammatory response. They suggested that the tumor cell attachment was closely linked to the host inflammatory response.

Tobai (59) investigated the mechanisms of dissemination of Yoshida sarcoma cells after intraperitoneal inoculation in rats. From 6 to 12 hr after inoculation, numerous Yoshida sarcoma cells were found in the milky spots which were enlarged by an increased number of macrophages, lymphocytes, and neutrophil leukocytes. Yoshida sarcoma cells proliferated in the milky spots to form tumor nodules with neovascularization. Tobai determined the significance of the milky spots as early targets for disseminated intraperitoneal cancer. In humans, cancer cells were also detected in milky spots (94,95).

Lawrance et al (96) studied the omentum in the development of tumors at sites of intraabdominal trauma (anastomotic and laparotomy wounds) using rat experimental models. They demonstrated a significant reduction in the "take" of tumor in trauma sites following intraperitoneal or intraluminal inoculation when maximal amounts of omental tissue were removed. Because stimulation of omental macrophages results in increased tumor on the omentum (97), Lawrance et al theorized that macrophage activity in omental milky spots led to secretion of polypeptide growth factors which enhanced tumor growth. Secretion of angiogenic factors from the omentum (80,97) may also result in early neovascularization of seeded tumor and more rapid growth.

Milky spots may be appropriate as the target organ in each step of tumor cell metastasis. Cancer cells usually form clumps in ascitic fluid (98), and have a high chance of attaching to the omentum because omentum takes part in fluid drainage from the peritoneal cavity. For tumor cell infiltration, exfoliation of mesothelial cells and degra-

dation of basement membrane appear to be essential steps (99,100). Concerning these steps, milky spots seem to be easily infiltrated by tumor cells because their surface is not completely covered by mesothelial cells (10,14-16,18,92) which lack basement membranes (10,14,15,18,33,44). These structural characteristics facilitate invasion of milky spots by cancer cells.

SIGNIFICANT FEATURES OF MILKY SPOTS IN INTRAPERITONEAL IMMUNOTHERAPY

In recent years, intraperitoneal immunotherapy has been widely used as adjuvant postsurgical or palliative treatment of intraperitoneal malignant diseases (101-103). Intraperitoneal administration is an anatomically appropriate route because it directly introduces the biological response modifiers (BRMs) to the involved areas in the peritoneal cavity. This therapy is based on the concept that the optimal BRMs augment host resistance to malignant tumors by specific and/or non-specific immunity. Whereas the mechanism of immunotherapeutic activity in the peritoneal cavity has not yet been elucidated in detail, peritoneal macrophages are known important effector cells in the host defense against tumors and metastases. In this regard, the omental milky spots which generate peritoneal macrophages have potentially important anti-tumor host defense activity.

Rasmussen and Seljelid (104) investigated cytokine release after the intraperitoneal administration of β -1, 3-D-polyglucose treated microbeads (GDM). They observed numerous GDM phagocytosed by milky spot macrophages 48 hr after administration, and significant amounts of interleukin 1 (IL-1) and prostaglandin E2 were released from the stimulated peritoneal macrophages.

In rats, intraperitoneal administration of a killed streptococcal preparation, OK-432, could prove to be an effective BRM for managing malignant ascites (102) by activating the milky spots and milky spot

macrophages (68). OK-432-activated macrophages demonstrated increased surface membrane activity and migration through the opening of the milky spots into the peritoneal cavity. The characteristic features of activated milky spots and milky spot macrophages suggest they are a valuable but under-utilized source of macrophages for intraperitoneal immunotherapy (68).

CONCLUSION

Since the era of Hippocrates (460-388 B.C.) physicians have been interested in the greater omentum (105). The omentum has been called the "policeman of the abdomen," the "friend in need" and the "great leucocyte" because of its protective role within the abdomen.

In the 19th century, milky spots were initially identified in the greater omentum as whitish spots formed by cellular aggregation, and were thought to have the ability to phagocytose foreign bodies in the peritoneal cavity.

More recently, however, omental milky spots have been recognized as omentum-associated lymphoid tissue which participate in intraperitoneal immune reactions (68,91,94). Macrophages covering the milky spots are oriented toward the peritoneal cavity, where they trap circulating antigens and transfer information to lymphocytes in the central zones of the milky spots. This functional cellular zonation seems to correspond to the structural relationship between macrophages lining the lymph sinus wall and lymphocytes in the germinal center of a lymph node. These omental milky spots likely represent an important immunoregulatory component for the peritoneal cavity.

REFERENCES

1. Morison, R: Functions of the omentum. *Br. Med. J.* 1 (1906), 76-78.
2. von Recklinghausen, F: Über Eiter-Bindegewebskörperchen. *Virchows Arch. Pathol. Anat.* 28 (1863), 157-166.
3. Fawcett, DW: *A Textbook of Histology*. 11th

- Edition. W.B. Saunders, Philadelphia, 1986, p. 164.
4. Ranvier, L: Du développement et de l'accroissement des vaisseaux sanguins. Arch. Physiol. Norm. Path. 6 (1874), 429-449.
 5. Hamazaki, Y: Comparative studies on the milky spots, 'taches laiteuses' of various animals. Folia. Anat. Jpn. 3 (1925), 243-265.
 6. Mixer, RL: On macrophagal foci ('milky spots') in the pleura of different mammals, including man. Am. J. Anat. 69 (1941), 159-186.
 7. Murata, J: Studies on macrophages in the peritoneal cavity. Report II. The origin of the macrophages in the peritoneal cavity. Acta. Haematol. Jpn. 18 (1955), 49-62.
 8. Tanaka, H: Comparative cytologic studies by means of an electron microscope on monocytes, subcutaneous histiocytes, reticulum cells in the lymph nodes and peritoneal macrophages. Ann. Report. Inst. Virus Research, Kyoto Univ. 1 (1958), 87-149.
 9. Riley, JF: *The Mast Cells*. London, E & S Livingstone, 1959, p. 54-55.
 10. Felix, MD: Observations on the surface cells of the mouse omentum as studied with the phase-contrast and electron microscopes. J. Natl. Cancer Inst. 27 (1961), 713-745.
 11. Mims, CA: The peritoneal macrophages of mice. Br. J. Exp. Path. 45 (1964), 37-43.
 12. Aronson, M, A Shahar: Formation of histiocytes by the omentum *in vivo*. Exp. Cell Res. 38 (1965), 133-143.
 13. Kaboth, U, W Ax, H Fisher: Zur Immunomorphologie der 'plaquebildenden' Milchflecken im Mäuseomentum. Z. Naturforsch 21 (1966), 789-793.
 14. Carr, I: The fine structure of the cells of the mouse peritoneum. Z. Zellforsch 80 (1967), 534-555.
 15. Bartoszewicz, W, K Dux: Electronmicroscopic studies of omental milk spots in normal mice. Nowotwory 18 (1968), 225-230.
 16. Dux, K: Role of the greater omentum in the immunological response of mice and rats to the intraperitoneal inoculation of Ehrlich ascites tumor. Arch. Immunol. Ther. Exp. 17 (1969), 425-432.
 17. Carr, I: The fine structures of the mammalian lymphoreticular system. Int. Rev. Cytol. 27 (1970), 283-348.
 18. Hodel, C: Ultrastructural studies on the absorption of protein markers by the greater omentum. Eur. Surg. Res. 2 (1970), 435-449.
 19. Kanazawa, K, MSC Birbeck, RL Carter, et al: Migration of asbestos fibers from subcutaneous injection site in mice. Br. J. Cancer 24 (1970), 96-106.
 20. Hajdu, I, M Holub, I Trebichavsky: The sequence of appearance of antibodies in mouse omentum plasma cells. Exp. Cell Res. 75 (1972), 219-230.
 21. Watanabe, K, S Masubuchi, K Kageyama: Ultrastructural localization of peroxidase in mononuclear phagocytes from the peritoneal cavity, blood, bone marrow and omentum, with a special reference to the origin of peritoneal macrophages. Recent Adv. RES Res. 11 (1973), 120-144.
 22. Szaniawska, B: Changes in the greater omentum of mice of different strains after intraperitoneal immunization with sheep erythrocytes. I. Production of IgM immunoglobulins in milky spots. Arch. Immunol. et. Ther. Exp. 22 (1974), 585-593.
 23. Szaniawska, B: Changes in the greater omentum of mice of different strains after intraperitoneal immunization with sheep erythrocytes. II. Study of the milky spot cells to reconstitute the humoral-type immunologic response in lethally irradiated mice. Arch. Immunol. et. Ther. Exp. 23 (1975), 11-17.
 24. Szaniawska, B: Changes in the greater omentum of mice of different strains after intraperitoneal immunization with sheep erythrocytes. III. Determination of the percentage of thymus-dependent cells in the omental milky spots in mice by the application of anti- θ serum. Arch. Immunol. et. Ther. Exp. 23 (1975), 19-24.
 25. Orenstein, JM, E Shelton: Surface topography of leukocytes *in situ*: Cells of mouse peritoneal milky spots. Exp. Mol. Pathol. 24 (1976), 415-423.
 26. Dux, K, P Janik, B Szaniawska: Kinetics of proliferation, cell differentiation, and IgM secretion in the omental lymphoid organ of B10/Sn mice following intraperitoneal immunization with sheep erythrocytes. Cell Immunol. 33 (1977), 97-109.
 27. Hatsuya, H: Mouse peritoneal macrophage reaction to Gutta percha *in vivo* and *in vitro*. Jpn. J. Exp. Med. 48 (1978), 167-176.
 28. Kanazawa, K, FJC Roe, T Yamamoto: Milky spots (Taches laiteuses) as structures which trap asbestos in mesothelial layers and their significance in the pathogenesis of mesothelial neoplasia. Int. J. Cancer 23 (1979), 858-865.
 29. Kanazawa, K, T Yamamoto, Y Yuasa: Enhancement by asbestos of oncogenesis by Moloney murine sarcoma virus in CBA mice. Int. J. Cancer 23 (1979), 866-874.
 30. Madison, LD, B Bergstrom-Porter, AR Torres, et al: Regulation of surface topography of mouse peritoneal cells. J. Cell Biol. 82 (1972), 783-797.

31. Takemori, N: Morphological studies of the omental milky spots in the mouse: Light and electron microscopy. *Hokkaido Igaku Zasshi* 54 (1979), 265-283.
32. Takemori, N: Milk spots on the parietal peritoneum over the pancreas in the mouse. *Hokkaido Igaku Zasshi* 54 (1979), 379-385.
33. Beelen, RHJ, DM Fluitsma, ECM Hoefsmit: The cellular composition of omentum milky spots and the ultrastructure of milky spot macrophages and reticulum cells. *J. Reticuloendothel. Soc.* 28 (1980), 585-599.
34. Beelen, RHJ, DM Fluitsma, ECM Hoefsmit: Peroxidatic activity of mononuclear phagocytes developing in omentum milky spots. *J. Reticuloendothel. Soc.* 28 (1980), 601-609.
35. Daems, WT, JM de Bakker: Do resident macrophages proliferate? *Immunobiol.* 161 (1982), 204-211.
36. Matsuno, K, T Schaffner, HA Gerber, et al: Uptake by enterocytes and subsequent translocation to internal organs, eg, the thymus, of Percoll microspheres administered per os to suckling mice. *J. Reticuloendothel. Soc.* 33 (1983), 263-273.
37. Kanazawa, K: Exchanges through the pleura. Cells and particles. In: *The Pleura in Health and Disease*. Chrétien, J. et al (Eds.), Dekker, New York, 1985, p. 195-231.
38. de Bakker, JM, AW de Wit, H Woelders, et al: On the origin of peritoneal resident macrophages. II. Recovery of the resident macrophage population in the peritoneal cavity and in the milky spots after peritoneal cell depletion. *J. Submicrosc. Cytol.* 17 (1985), 141-151.
39. Dux, K: Proliferative activity of macrophages in the greater omentum of the mouse in relation to the early postnatal development of the vascular structures. *J. Leukoc. Biol.* 40 (1986), 445-458.
40. Dux, K, RV Rouse, B Kyewski: Composition of the lymphoid cell populations from omental milky spots during the immune response in C57BL/Ka mice. *Eur. J. Immunol.* 16 (1986), 1029-1032.
41. Satoh, Y: Experimental study on the accumulation of tumor ascites in mice. *Fukushima J. Med. Sci.* 36 (1986), 357-375.
42. Ratajczak, MZ, D Jaskulski, Z Pojda, et al: Omental lymphoid organ as a source of macrophage colony stimulating activity in peritoneal cavity. *Clin. exp. Immunol.* 69 (1987), 198-203.
43. Dux, K: Anatomy of the greater omentum and lesser omentum in the mouse with some physiological implications. In: *The Omentum. Research and Clinical Applications*. Goldsmith, H. (Ed.), Springer-Verlag, New York, 1990, p. 19-43.
44. Cranshaw, ML, LV Leak: Milky spots of the omentum: A source of peritoneal cells in the normal and stimulated animal. *Arch. Histol. Cytol.* 53 (1990), 165-177.
45. Magari, S, Y Mizutani, K Fujikawa, et al: Structure of lymphatics and lymph flow. *Myakkangaku* 19 (1979), 151-157.
46. Renault, J: Les cellules connectives rhagiocrines. *Arch. Anat. Microsc.* 9 (1902), 475.
47. Webb, RL: Peritoneal reactions in the rat, with special reference to the mast cells. *Am. J. Anat.* 49 (1931), 283-334.
48. Latta, JS, DI Rutledge: The reaction of omental tissues to trypan blue injected intraperitoneally, with special reference to interrelationships between cell types. *Am. J. Anat.* 56 (1935), 481-511.
49. Baillif, RN: Reaction of rat omentum to injections of particulate matter. *Proc. Soc. Exp. Biol.* 47 (1941), 409-414.
50. Cooray, GH: Defensive mechanisms in the mediastinum, with special reference to the mechanics of pleural absorption. *J. Path. Bact.* 61 (1949), 551-567.
51. Riley, JF: The relationship of the tissue mast cells to the blood vessels in the rat. *J. Path. Bact.* 65 (1953), 461-469.
52. Imai, Y, T Kasajima, M Matsuda: Electron-microscopic study on the peritoneal macrophage and milky spot in omentum. *Recent. Adv. RES Res.* 11 (1971), 54-84.
53. Skurzak, H, K Dux: Immunofluorescent of milky spots of rats inoculated with Ehrlich ascites tumor cells. *Nowotwory* 21 (1971), 103-106.
54. Yong, LC, S Watkins, DL Wilhelm: The mast cell: Distribution and maturation in the peritoneal cavity of the adult rat. *Pathology* 7 (1975), 307-318.
55. Yong, LC, S Watkins, DL Wilhelm: The mast cell: II. Distribution and maturation in the peritoneal cavity of the young rat. *Pathology* 9 (1977), 221-232.
56. Suzuki, G: Milky spot, as a source of ascitic mast cells in rat. *J. Kyoto Pref. Univ. Med.* 85 (1976), 679-692.
57. Green, J, AE Williams: The relationship between inflammatory responses and WBP1 tumor cell attachment to the rat omentum. *Eur. J. Cancer* 14 (1978), 1153-1155.
58. Mironov, VA, SA Gusev, AF Baradi: Mesothelial stomata overlying omental milky spots: Scanning electron-microscopic study. *Cell Tissue Res.* 201 (1979), 327-330.
59. Tobai, S: Electronmicroscopic studies on the invasion and intravasation of Yoshida sarcoma cells in the omentum. *Fukushima J. Med. Sci.*

- 31 (1981), 31-46.
60. Mandache, E, E Moldoveanu, G Savi: The involvement of omentum and its milky spots in the dynamics of peritoneal macrophages. *Morphol. Embryol.* 31 (1985), 137-142.
 61. Imai, Y, M Yamada, K Maeda, et al: Omental milky spot and peritoneal macrophage. Characteristics, function and ontogeny. *J. Jpn. Soc. Clin. Cytol.* 26 (1987), 572-580.
 62. Mandache, E, E Moldoveanu, A Negoescu: Lymphatic follicle-like structures in the stimulated omental milky spots. *Molphol. Embryol.* 33 (1987), 285-289.
 63. Beelen, RHJ, IL Estermans, EA Dopp, et al: Immunological characteristics of milky spots in the omentum of rats. *Adv. Exp. Med. Biol.* 237 (1988), 745-750.
 64. Shimotsuma, M, T Takahashi, A Hagiwara, et al: Staining of macrophages in rat omental milky spots using Leucomethylene blue (Neurostain). *J. New Remedi. Clinic.* 37 (1988), 1217-1222.
 65. Webb, RL, PH Simer: The relation of lymph vessels to omental milky spots. *Anat. Rec.* 83 (1942), 437-447.
 66. Mandache, E, A Negoescu, E Moldoveanu: The development of lymphatic follicles in the omentum after intraperitoneal stimulation of rats. *Morphol. Embryol.* 35 (1989), 139-147.
 67. Kremli, SM, SG Mamontov: Morphological features of milky spots of the rat omentum in inflammation. *Biull. Eksp. Biol. Med.* 109 (1990), 616-619.
 68. Shimotsuma, M, MW Simpson-Morgan, T Takahashi, et al: Activation of omental milky spots and milky spot macrophages by intraperitoneal administration of a Streptococcal preparation. OK-432. *Cancer Res.* 52 (1992), 5400-5402.
 69. Zweifach, BW, HH Lipowsky: Quantitative studies of microcirculatory structure and function. III. Microvascular hemodynamics of cat mesentery and rabbit omentum. *Circ. Res.* 41 (1977), 380-390.
 70. Intaglietta, M, BW Zweifach: Geometrical model of the microvasculature of rabbit omentum from *in vivo* measurements. *Circ. Res.* 28 (1971), 593-600.
 71. Lang, J: Über die Gefäße und die Zellen der Milchflecken. *Z. Zellforsch.* 66 (1965), 1-27.
 72. Lang, J, HG Liebich: Über eigenartige Kapillarkonvolute der Pleura parietalis. *Z. Mikrosk. Anat. Forsch.* 90 (1976), 1074-1092.
 73. Trebichavsky, I, M Holub, L Jaroškov, et al: Ontogeny of lymphatic structures in the pig omentum. *Cell Tissue Res.* 215 (1981), 437-442.
 74. Brandt, A, B Schnorr: The vascular supply of the greater omentum in sheep and goat. *Z. Mikrosk. Anat. Forsch.* 97 (1983), 427-440.
 75. Seifert, E: Zur Biologie des menschlichen großen Netzes. *Arch. Klin. Chir.* 116 (1921), 510-517.
 76. Kampmeier, OF: Concerning certain mesothelial thickenings and vascular plexuses of the mediastinal pleura, associated with histiocyte and fat-cell production, in the human newborn. *Anat. Rec.* 39 (1928), 201-208.
 77. Aharinejad, S, P Franz, W Firbas: The milky spots on the chest wall in newborns. *Acta Anat.* 138 (1990), 341-347.
 78. Shimotsuma, M, M Kawata, A Hagiwara, et al: Milky spots in the human greater omentum. Macroscopic and histological identification. *Acta Anat.* 136 (1989), 211-216.
 79. Goldsmith, HS, T McIntosh, RM Vezina, et al: Vasoactive neurochemicals identified in omentum: A preliminary report. *Br. J. Neurosurg.* 1 (1987), 359-364.
 80. Goldsmith, HS, AL Griffin, A Kupfermann: Lipid angiogenic factor from the omentum. *JAMA* 252 (1984), 2034-2036.
 81. Edvinsson, L, R Hakanson, S Steen, et al: Innervation of human omental arteries and veins and vasomotor responses to noradrenaline, neuropeptide Y, substance P and vasoactive intestinal peptide. *Regul. Peptides* 12 (1985), 67-79.
 82. Casparis, HR: Lymphatics of the omentum. *Anat. Rec.* 15 (1918), 93-99.
 83. Simer, PH: On the morphology of the omentum, with especial reference to its lymphatics. *Am. J. Anat.* 54 (1934), 203-228.
 84. Simer, PH: Omental lymphatics in man. *Anat. Rec.* 63 (1935), 253-262.
 85. Yoffey, JM, FC Courtice: *Lymphatics, Lymph, and the Lymphomyeloid Complex*. Academic Press, London, 1970, p. 295-305.
 86. Zweifach, BW, GW Schmid-Schönbein: Pressure and flow relations in the lymphatic system. In: *Experimental Biology of the Lymphatic Circulation*. Johnston, MG (Ed.), Elsevier, Amsterdam, 1985, p. 46-79.
 87. Kihara, T: Das extravaskuläre Saftbahnsystem. *Okajima Folia Anat. Jap.* 28 (1956), 601-621.
 88. Borisov, A: Lymphatic capillaries and vessels of milky spots in human great omentum. *Arkh. Anat. Gistol. Embriol.* 44 (1963), 150-154.
 89. Shimotsuma, M, T Takahashi, M Kawata, et al: Cellular subsets of the milky spots in the human greater omentum. *Cell Tissue Res.* 264 (1991), 599-601.
 90. Hagiwara, A, T Takahashi: A new drug-delivery-system of anticancer agents: Activated carbon particles adsorbing

- anticancer agents. *In Vivo* 1 (1987), 241-252.
91. Shimotsuma, M, M Shirasu, A Hagiwara, et al: Omental milky spots and the local immune response. *Lancet* 339 (1992), 1232.
 92. Shimotsuma, M, A Hagiwara, T Takahashi, et al: Surface structure and cell zonation in human omental milky spots. *Lymphology* 23 (1990), 207-208.
 93. Portis, B: Role of omentum of rabbits, dogs, and guinea-pigs in antibody production. *J. Infect. Dis.* 34 (1924), 159-185.
 94. Shimotsuma, M, MW Simpson-Morgan: Omental milky spots. *Lancet* 338 (1991), 1596.
 95. Shimotsuma, M, M Itoh, T Sasabe, et al: Role of omental milky spots in peritoneal metastases of carcinoma. *Oncologia* 24 (1991), 80-85.
 96. Lawrance, RJ, M Loizidou, AJ Cooper, et al: Importance of the omentum in the development of intra-abdominal metastases. *Br. J. Surg.* 78 (1991), 117-119.
 97. Murphy, P, P Alexander, PV Senior, et al: Mechanisms of organ selective tumour growth by blood-borne cancer cells. *Br. J. Cancer* 57 (1988), 19-31.
 98. Sampson, JA: The origin and significance of newly formed lymph vessels in carcinomatous peritoneal implants. *Am J. Pathol.* 12 (1936), 432-467.
 99. Birbeck, MSC, DN Wheatley: An electron microscopic study of the invasion of ascites tumor cells into the abdominal wall. *Cancer Res.* 25 (1965), 490-497.
 100. Terranova, VP, ES Hujanen, GR Martin: Basement membrane and the invasive activity of metastatic tumor cells. *J. Natl. Cancer Inst.* 77 (1986), 311-316.
 101. Bast, RC, JS Berek, R Obrist, et al: Intraperitoneal immunotherapy of human ovarian carcinoma with *Corynebacterium parvum*. *Cancer Res.* 43 (1983), 1395-1401.
 102. Torisu, M, M Katano, Y Kimura, et al: New approach to management of malignant ascites with a Streptococcal preparation, OK-432. I. Improvement of host immunity and prolongation of survival. *Surgery.* 93 (1983), 357-364.
 103. Eggermont, AMM, PH Sugarbaker: Intraperitoneal chemotherapy and immunotherapy. *Onkologie.* 14 (1991), 123-136.
 104. Rasmussen, LT, R Seljelid: Novel immunomodulators with pronounced *in vivo* effects caused by stimulation of cytokine release. *J. Cell Biochem.* 46 (1991), 60-68.
 105. Walker, FC: The protective function of the greater omentum. *Ann. Roy. Coll. Surg. Engl.* 33 (1963), 282-306.

Masataka Shimotsuma, M.D., Ph.D.
First Department of Surgery
Kyoto Prefectural University of Medicine
Kamigyo-ku, Kyoto 602
JAPAN