

SPECIES VARIATION IN THE EXTRINSIC LYMPHATIC DRAINAGE OF THE RODENT TESTIS: Its Role Within the Context of an Immunologically Privileged Site

A.A. Kazeem

Department of Clinical Pathology, College of Medicine, University of Lagos, Lagos, Nigeria

ABSTRACT

Earlier work suggested that the immunologically privileged site of the rat testis was associated with anomalous testicular lymph drainage whereby some lymphatic trunks bypassed regional lymph nodes and opened directly into the systemic blood circulation via the cisterna chyli and thoracic duct. Because other workers also noted the privileged status of the testes in untreated mice and guinea pigs, we opted to examine the nature of the testicular extrinsic lymphatic system in these rodents using the rat model for comparison.

Contrary to expectation, there were no direct lymphatic-venous communications draining the testes of either guinea pigs or mice. Instead, testicular lymphatics drained into at least one lymph node before reaching the blood circulation. This disparity from testicular lymphatic drainage of the rat suggests that the immunologic privilege, if any, in mice and guinea pigs has an alternative explanation (e.g., lymphatic effect of steroidal factors emanating from the testicles or adrenal gland and altering the response to foreign graft).

The study of immunologically privileged sites has provided a model system for possible survival of small tissue allografts without the use of immunosuppressive agents. Earlier studies suggested that the immunologic privilege status of the rat testis is related to an anomalous drainage of the testicular lymph trunks, which bypassed retroperitoneal lymph nodes and opened directly into the venous cir-

ulation via the cisterna chyli (1-3). Gardner and Hill (4) reported the survival of anterior pituitary allografts within the testis of an outbred strain of mice as judged histologically. Similarly, Aaron and coworkers (5) found that the guinea pig testes were unusually tolerant to endocrine allotransplant such as thyroid tissue and pars distalis of the pituitary. The surviving intratesticular thyroid allograft responded to thyroid-stimulating hormone and showed suppression after administration of thyroxine. Furthermore, the host succumbed after extirpation of established allogeneic thyroid tissue (6). Ferguson and Scotthorne also described extended survival of pancreatic islet and skin allografts within the testes of guinea pig (7-9).

These accounts of continued survival and occasionally proliferation of foreign tissue grafts within the testes of untreated mice and guinea pigs suggest that the reproductive organ in these rodents is immunologically privileged. By analogy with the rat testis, this privilege in the guinea pig and mice testes may also be similarly related to direct lymphatic-venous communication bypassing regional lymph nodes, a consideration that forms the basis of this investigation.

MATERIALS AND METHODS

Inbred strains of 40 adults male Duncan-Hartley guinea pigs, 40 CBA strain of mice, and 40 Albino-Swiss rats were obtained from the animal house unit of the College of Medicine, University of Lagos. They were fed standard pellets commercially prepared by

Livestock Feeds Ltd., Lagos. Water was given ad libitum.

Injection materials

The injection materials used to visualize lymphatic collectors were pontamine sky blue 0.5% in distilled water (High Wycombe, Bucks, England) and india ink (Winzor & Newton Ink., England) diluted 1:4 with distilled water and filtered 4-6 times to prevent large dye particles plugging smaller lymph vessels.

Injection technique

The approach to lymphatic injection was modified from earlier description (2). To facilitate identification of lymph nodes, 0.5% pontamine sky blue was injected into the peritoneal cavity of each animal studied, at an average dose of 1ml/100gm of body weight. An interval of one to three weeks was allowed (i.e., when the sclerae no longer showed coloration with the dye).

Each animal was anesthetized with ether and a midline abdominal incision was extended into both sides of the scrotum in order to deliver the testes. The flaps of the anterior abdominal wall were reflected onto the sides. The superficial lymphatic plexus beneath the tunica albuginea of each testis was injected with diluted and filtered india ink.

Several minutes after injection, migration of the ink into primary retroperitoneal lymph nodes and/or the cisterna chyli enroute to the venous circulation via the thoracic duct was ascertained. At this stage, each animal was subject to ether overdosage and the organs perfused with a solution of Ringer's lactate via a catheter introduced into the thoracic aorta. Blood was washed out via a hole opened into the right ventricle. In this way, tissues and organs were flushed of blood and the resultant extreme background pallor provided a sharp contrast for highlighting india ink filled collecting lymph trunks emanating from the testis.

RESULTS

Guinea pig testicular lymph drainage

After both testes of each guinea pig were injected with india ink, the efferent lymphatics from each gonad drained superiorly bypassing the lower para-aortic group of lymph nodes. At the level of the kidney, each efferent lymph trunk divided into several branches (*Fig. 1*). These branches anastomosed among themselves in the form of arcades and communicated with contralateral draining lymphatics. This cross-linking of lymph vessels uniformly resulted in a complex network from which the testicular lymph trunks bilaterally emptied into a group of pararenal nodes. The location of the testicular regional nodes was consistently superior to the distal para-aortic nodes near the axis joining the hilum of each kidney. However, the numbers and sizes of these lymph nodes varied considerably. Although a painstaking search was made for direct lymphatic-venous communication, no injected india ink was seen passing from lymph vessels into adjacent veins. Indeed, all lymph trunks were intercepted by at least one lymph node before entry into the cisterna chyli.

Mouse testicular lymph drainage

The mouse testicular lymph trunks on both sides drained cranialwards and emptied into at least one node on the ipsilateral side or sometimes crossed to the opposite side before nodal interception (*Fig. 2*). There was, however, considerable variation in the drainage pattern. In the most common (~86%), the testicular lymph trunk first drained into one of the lower para-aortic group of nodes and thereafter the efferent lymphatic either connected to an ipsilateral or contralateral superior para-aortic node or occasionally with a pararenal node. Again, there was no direct communication between the afferent testicular lymph trunk and the cisterna chyli nor any direct lymphatic-venous communication.

Guinea Pig

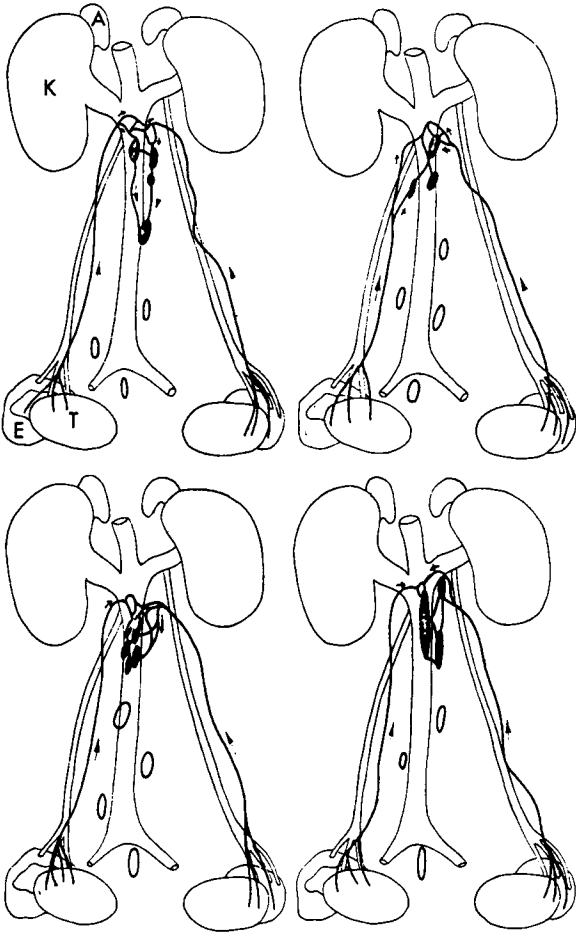


Fig. 1. Extrinsic testicular lymph trunks of four guinea pigs. Each trunk divides into several branches at the renal axis forming an anastomotic network that drains into a group of para-aortic nodes. Lymph trunks are uniformly intercepted by at least one lymph node before communicating with the cisterna chyli.

Rat testicular lymph drainage

The pattern of testicular lymph trunks was nearly identical to earlier accounts (2) and updated in transplantation studies (3). The left testicular trunk was uniformly interrupted by at least one lymph node. By contrast, the right

trunk in 12 of 40 rats opened directly into the cisterna chyli (Fig. 3).

DISCUSSION

The present study compared the testicular lymphatic drainage in guinea pigs, rats, and mice. In contrast to rats, testicular lymph drainage in guinea pigs and mice consistently drained into regional lymph nodes before joining the cisterna chyli or the venous system. There were no direct lymphatic-venous communication. Technically, the testicular extrinsic lymph trunks and draining nodes appeared to be satisfactorily demonstrated. Pontamine sky blue previously injected into the peritoneum was well retained within the lymph nodes at the time each animal was killed. This nodal coloration allowed easy identification of the nodes. Use of india ink allowed ink particle movement to and fro to be seen in the cisterna chyli within dilated lymphatics or between valves under the dissecting microscope. Lymph nodes were firm in consistency and spread of the ink around the nodal convex border before reaching the hilum was readily detected. Moreover, the background pallor after aortic perfusion with washout of blood provided vivid contrast. These considerations may explain the disparity between our findings in the rat and contradictory reports of others (10-12).

Testicular lymph trunks are uniformly interrupted by at least one lymph node in mice, guinea pigs, and on the left side of Albino-swiss rats. What is the relation of these results on understanding the immunologic privilege of the rodent testis? Because in mice and guinea pigs lymphatic trunks draining the testis are interrupted by at least one node before entering the cisterna chyli, this finding rules out that immunologic tolerance of allografts in the testis of these rodent species relates to diversion and possible release of alloantigens directly into the bloodstream. By contrast, anomalous lymphatic-venous communications in the rat was found to favor tissue allograft survival (8).

Mouse

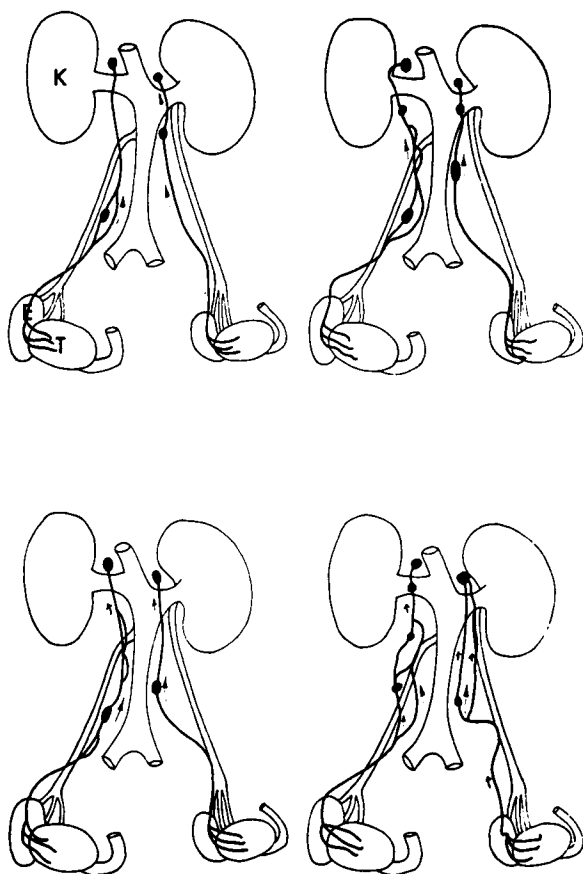


Fig. 2. Extrinsic testicular lymph trunks of four mice. Lymphatic trunks are consistently intercepted by at least one para-aortic node before communicating with the cisterna chyli. There is considerable variation in the details of the drainage pattern.

Rat

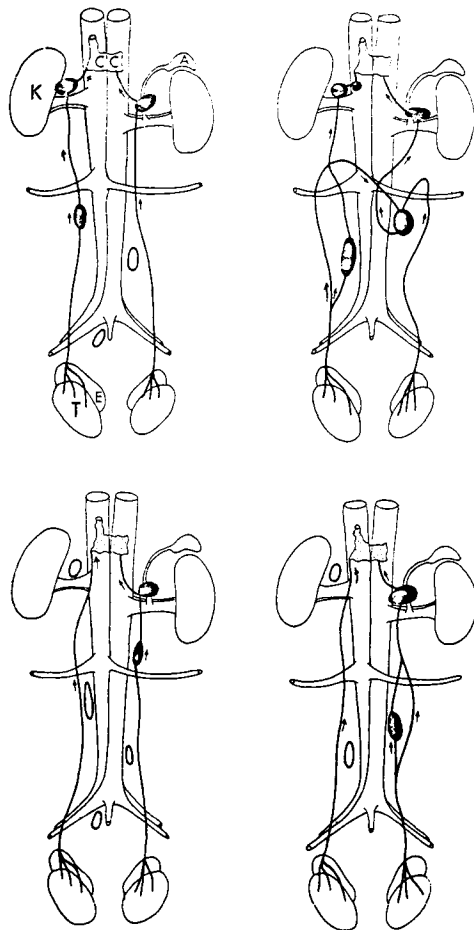


Fig. 3. Extrinsic testicular lymph trunks of four rats. The two upper drawings show that the testicular lymph trunks are intercepted by at least one para-aortic node. By contrast, the right testicular lymphatic trunks (lower illustrations) entirely bypass retroperitoneal nodes and opened directly into the cisterna chyli.

Previously we examined (13) the histological features of rat lymph nodes primarily intercepting testicular lymph trunks especially at the level of the renal axis. These lymph nodes appeared "inactive" or quiescent with poorly developed cortical nodules, absent or sparse germinal centers, inconspicuous thymus

dependent cortex, narrow medullary cords and isolated plasma cells (13). These appearances may be due in part to lympholytic factors such as endogenous steroids that reach the nodes via testicular lymph trunks. When the primary lymph nodes are situated at the level of the renal axis, other factors from the adrenal gland may act synergistically. It is reasonable to pos-

tulate that these steroidal factors may alter the response to an intratesticular allograft.

REFERENCES

1. Kazeem, AA: The assessment of epididymal lymphatics within the context of immunologically privileged sites. *Lymphology* 16 (1983), 168-171.
2. Kazeem, AA: Reexamination of testicular lymphatic drainage in the rat. *Lymphology* 19 (1986), 172.
3. Kazeem, AA: A critical consideration of the rat epididymis as an immunologically privileged site. *Scan. J. Immunol.* 27 (1988), 149-156.
4. Gardner, WU, RT Hill: Persistence of pituitary grafts in testis of mouse. *Proceedings Soc. Exp. Biol. Med.* 32 (1935), 1382-1384.
5. Aaron, M, J Marescaux, A Petrovic: Graffes homoplastiques intratesticulaires chez les mammifères. In: *La Biologie des Homogreffes*. Colloques Internationaux du Centre National de la Recherche Scientifique 78 (1957), 2-10.
6. Fabre, M, J Marescaux: La thyro ostimuline est-elle "métabolisée" par son effecteur thyroïdien? *Compte rendu de la Société de Biologie* 152 (1958), 1385-1387.
7. Ferguson, J, RJ Scothorne: Extended survival of pancreatic islet allografts in the testis of guinea pigs. *J. Anat.* 124 (1977), 1-8.
8. Ferguson, J, RJ Scothorne: Further studies on the transplantation of isolated pancreatic islet. *J. Anat.* 124 (1977), 9-20.
9. Patrick, D, JM Myers, RJ Scothorne: The fate of skin allografts in normal and experimentally altered guinea pig testis. *J. Anat.* 111 (1972), 472.
10. Tilney, NL: Patterns of lymphatic drainage in the adult laboratory rat. *J. Anat.* 109 (1971), 369-383.
11. McCullough, DL: Experimental lymphangiography: Experience with direct medium injection into parenchyma of the rat testis and prostate. *Invest. Urology* 13 (1975), 211-219.
12. Whitmore, WF, RF Gittes: Studies of the prostate and testis as immunologically privileged sites. *Cancer Treatment Report* 61 (1977), 217-222.
13. Kazeem, AA, O Reid, RJ Scothorne: Studies on hemolymph nodes. I. Histology of the renal hemolymph node of the rat. *J. Anat.* 134 (1982), 677-683.

**A.A. Kazeem, MB BS, C. Imm.,
Ph.D.-Glasgow
Department of Clinical Pathology
College of Medicine
University of Lagos
P.M.B. 12003
Lagos, NIGERIA**