

FIBROSCLEROTIC LYMPHEDEMA: PATHOPHYSIOLOGY AND THERAPY

F. Talarico, D. Brunetto, M. Scialabba, I. Pernice, G. Valenti, S. Benvegna, G. Mastrandrea, F. Rusignuolo

Department of Surgery and Anatomy, University of Palermo, Palermo, Italy

ABSTRACT

We describe our experience with 12 patients with severe fibrotic lymphedema treated between 1979 and 1987. Each patient initially underwent nonoperative treatment (postural drainage and pneumatic compression) and in 10 patients who required operation, these measures were continued postoperatively. Operation included excision of subcutaneous tissue (debulking), which was extensive in 8 and limited in 2 patients. Only 2 patients were satisfactorily managed by nonoperative treatment alone. Based on the extensive pathophysiologic changes that occur in the tissue microenvironment with lymph stasis, it is unlikely that at this advanced stage of lymphedema that nonoperative treatment alone or "physiologic" operations such as lymphatic-venous shunt or lymphatic collector reconstruction is satisfactory. Rather, nearly all such patients require limited or extensive excision of the fibrotic-edematous subcutaneous tissue.

Despite numerous nonoperative and operative treatment modalities for management of peripheral lymphedema, no single therapy has proved ideal. To a large extent this shortcoming relates to the underlying clinical condition (i.e., obstructive or hypoplastic lymphedema) and the pathogenesis of intense fibrosclerosis that accompanies long-term lymphedema. The lymphatic system is central to the removal of surplus fluid

and plasma proteins that ordinarily "leak" into the interstitium. Unique to this process are lymphatic capillary anchoring filaments (1) which facilitate opening of endothelial intercellular junctions and therefore facilitate lymphatic absorption with ongoing tissue edema. Propulsion of lymph forward depends primarily upon intrinsic lymphatic contractility in segments between intraluminal valves (so-called "lymphangions") (2) although lymph nodal pressure, local heat application, short-term external compression and regional permeability differences probably enhance lymphangion activity and thereby contribute to forward lymph flow (2,3).

With longstanding lymphedema, concentrations of tissue protein may approach that in plasma or 5-10x the normal amount (4). The increased tissue colloid osmotic pressure not only promotes greater interstitial edema but the increased sequestration of macromolecules and protein favor both greater fibrin and collagen deposition, aggravated in turn by down-regulation of tissue macrophage proteolysis (5). Subsequent interstitial fibrosis in conjunction with greater tissue hydrostatic pressure works to stiffen the anchoring filaments (6) further interfering with lymphatic clearance (7,8) and ultimately producing severe fibrosclerosis.

It is this sequence of events, based largely on experimental studies, that likely accounts for the progression to grotesque fibrosclerotic lymphedema (Fig. 1) and the limited success of current therapy.

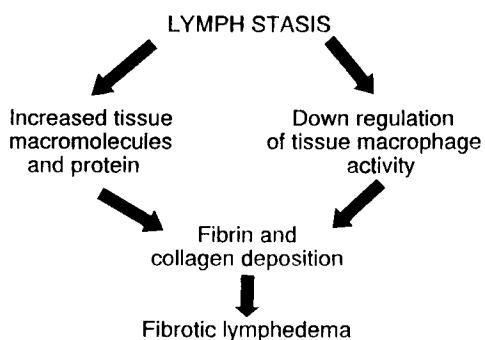


Fig. 1. Pathophysiology of fibrosclerotic lymphedema.

MATERIALS, METHODS, AND RESULTS

Between 1979 and 1987, 12 patients (4 male and 8 female) were treated for severe fibrotic lymphedema of the extremities (Fig. 2) at the Istituto di Patologia Chirurgica R of the University of Palermo (Director Prof. M. Florena). The patient ages were in the range of 43-68 years (mean 57 years).

In 2 patients the arms were involved, one following radical mastectomy and the other after regional irradiation. Of the remaining 10 patients with fibrotic lymphedema of the legs, 9 were primary (i.e., congenital) and one was secondary to cancer of the uterus. None were accompanied by deep venous thrombosis (Doppler scanning and/or phlebography).

For the first 5-10 days, each patient underwent postural drainage and pneumatic compression (9,10). Thereafter diagnostic evaluation included xeroradiography (Fig. 3), conventional lymphography (oil contrast)(Fig. 4), and "blue-dye test" (Fig. 5) to delineate better the subcutaneous layers, soft tissues and sometimes the lymphatic collectors. Information obtained was classified into four anatomic categories:

- 1) Dilatation of peripheral collectors (lymphatic varices)
- 2) Lymphatic hypoplasia
- 3) Lymphatic obliteration
- 4) Dermal backflow

Therapy consisted initially of drug treatment (benzopyrone) (5) and high pressure pneumatic compression (Lymphapress) (11). Where measurement of the ankle or wrist circumference showed little or no reduction in edema (10 patients), operative reduction was carried out. The procedures consisted of Thompson's "debulking" (2 patients) (Fig. 6) and subcutaneous excisional therapy as advocated by Charles (2 patients), Servelle (4 patients), and Lagrots-DeTakats (2 patients) (Fig. 7). In the other 2 patients, nonoperative treatment was satisfactory and was continued periodically. The results of the operative procedures were similar to that of others (12) being satisfactory in 9 patients and poor in 3. Follow-up was from 10 months to 5 years.

COMMENT

Because of the extensive changes accompanying severe fibrotic lymphedema, it is unlikely that nonoperative treatment alone can favorably influence the more or less permanent anatomic and functional interstitial damage sustained.

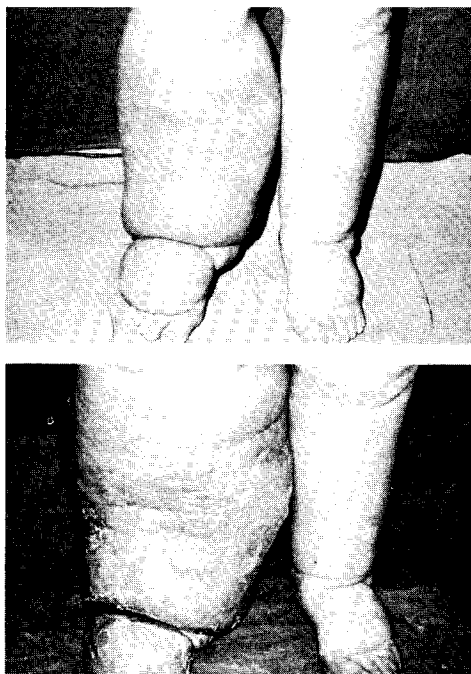


Fig. 2. Progressive fibrosclerotic lymphedema.

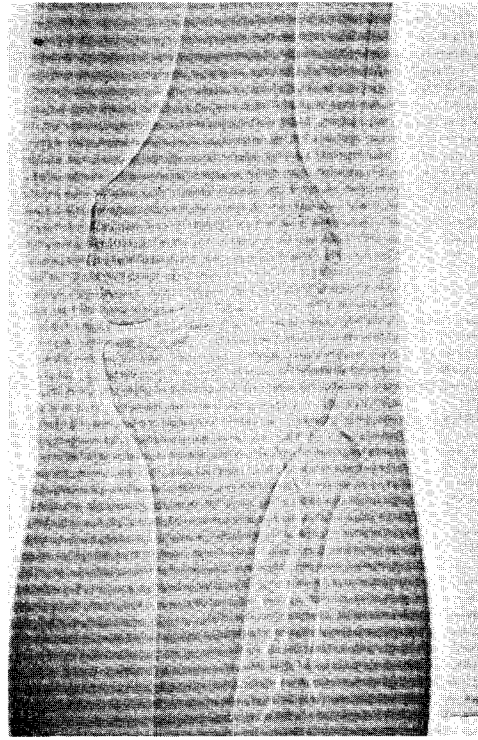
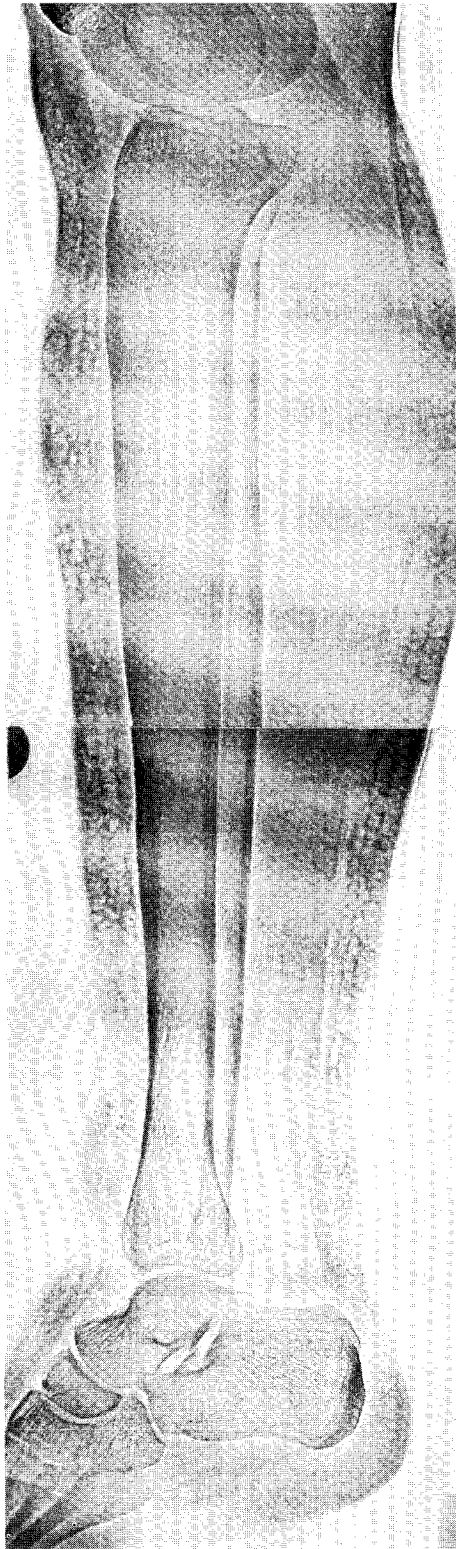


Fig. 3. (LEFT and ABOVE) Xeroradiograms of leg lymphedema demonstrating ectactic, tortuous lymphatics with "fibrosclerosis."

Similarly, it seems highly unlikely that operations such as lymphatic-venous, lymphatic-lymphatic, lymph nodal-venous shunts (13), or the more recent lymphatic-venous-lymphatic reconstructions (14) can improve apparently irreversible microenvironmental tissue injury. Accordingly, excisional therapy in conjunction with postural drainage and pneumatic compression before and after operation is favored to interrupt the vicious circle of progressive sclerosis (see Fig. 1). Where conventional lymphography demonstrates preservation of deep lymphatic integrity, Thompson's partial excisional therapy may be appropriate; otherwise, extensive lipofasciectomy is necessary. If advanced elephantiasis is accompanied by skin changes with severe acanthosis and warty overgrowth, lipofasciectomy in conjunction with skin removal may be required.

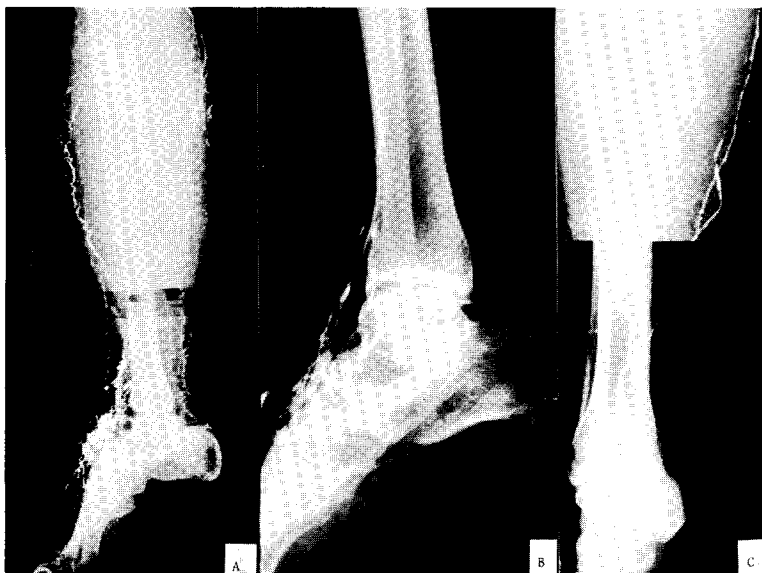

Fig. 4. Conventional lymphograms demonstrating lymphatic varices (A), lymphatic hypoplasia with perilymphatic collaterals (B), and lymphatic obliteration and reflux (C).

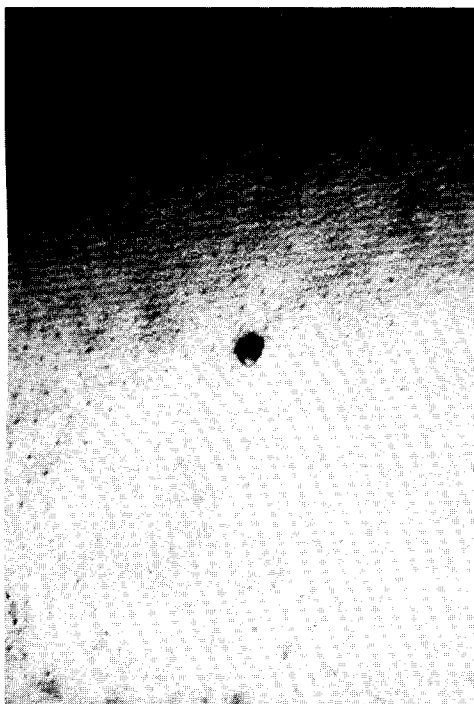


Fig. 5. Example of "dermal backflow" in a lymphoedematous limb after intradermal injection of blue-dye.

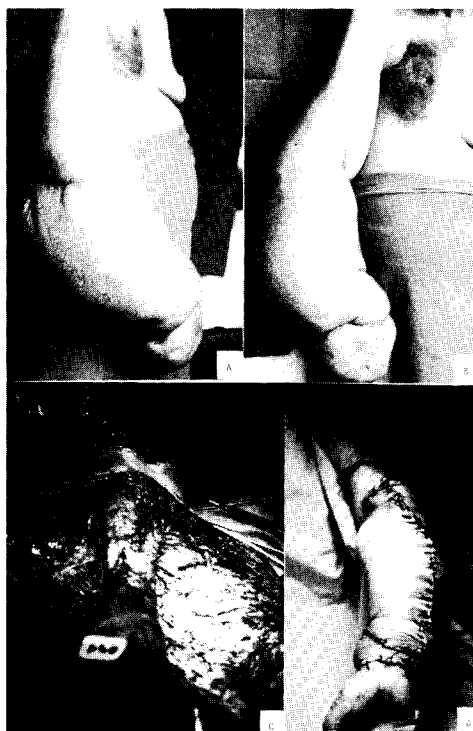


Fig. 6. Severe fibrosclerotic lymphedema (A,B) following mastectomy and chest wall irradiation for treatment of carcinoma of the breast. Intra-operative photographs (C,D) of Thompson's "de-bulking" operation.

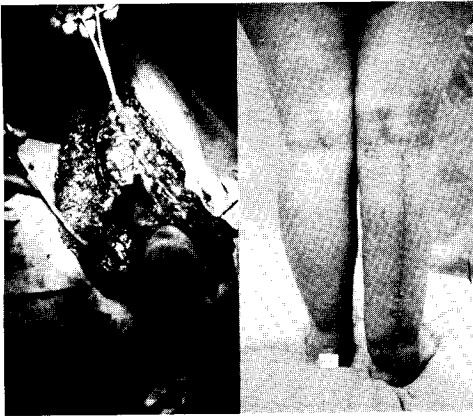


Fig. 7. Intraoperative photograph (left) and postoperative appearance (right) after Lagrot-de Takats "debulking" operation for right leg fibrosclerotic lymphedema.

REFERENCES

1. Casley-Smith, JR: The structure and functioning of the blood vessels, interstitial tissues and lymphatics. In *Lymphangiology*, Földi, M, JR Casley-Smith (Eds.), Shattauer Verlag, Stuttgart (1983), 94.
2. Mislin, H: The lymphangion. In *Lymphangiology*, (vide supra), 165.
3. Van der Molen, HR: La thérapeutique de la grosse jambe chronique par atteinte lymphatique. *Gaz Med. Fr.* 77 (1970), 1725.
4. Taylor, GW, JB Kinmonth, E Rollinson, et al: Lymphatic circulation studies with radioactive plasma protein. *Br. Med. J.* 1 (1957), 133.
5. Piller, NB: Lymphedema, macrophages and benzopyrones. *Lymphology* 13 (1980), 109.
6. Olivier, CL, JF Merlen: *Précis des maladies des vaisseaux*. Masson, Paris (1983)
7. Browse, NL: The diagnosis and management of primary lymphedema. *J. Vasc. Surg.* 3 (1986), 181.
8. Browse, NL, G Stewart: Lymphedema: Pathophysiology and classification. *J. Cardiovasc. Surg.* 26 (1985), 91.
9. Richmond, DM, TF O'Donnell, A Zelikovski: Sequential pneumatic compression for lymphedema: A controlled trial. *Arch. Surg.* 120 (1985), 10.
10. Zelikovski, A, M Haddad, R Reiss: Non-operative therapy combined with limited surgery in management of peripheral lymphedema. *Lymphology* 19 (1986), 106.
11. Zelikovski, A, M Haddad, R Reiss: Lymphapress, a new device for the treatment of lymphedema. *Lymphology* 13 (1980), 68.
12. Browse, N: *Reducing Operations for Lymphedema of Lower Limb--A Color Atlas*. Wolfe Med. Yearbook (1986).
13. Olszewski, WL: Indications for the treatment of lymphedema of extremities with microsurgical lymph-venous anastomoses. In *Lymphology: Advances in Europe*, Casaccia, M, C. Campisi (Eds.), g.e.l., Brussels (1989), 207.
14. Campisi, C: Autologous vein grafts for microsurgical reconstruction of lymph vessels. II part: Microsurgical technique and clinical results. In *Lymphology: Advances in Europe*, (vide supra), 273.

Dr. Francesco Talarico
via Due Vanelle n°24
90131 Palermo, ITALY