

LYMPHOGRAPHIA**³¹P-MR SPECTROSCOPY OF SKELETAL MUSCLE IN A LYPHEDEMATOUS ARM**

I.C. Kiricuta, R. Blümm, H.-W. Krawzak, H.K. Beyer

Departments of Radiology and Surgery (H-WK), Marienhospital, Herne University of Bochum, West Germany

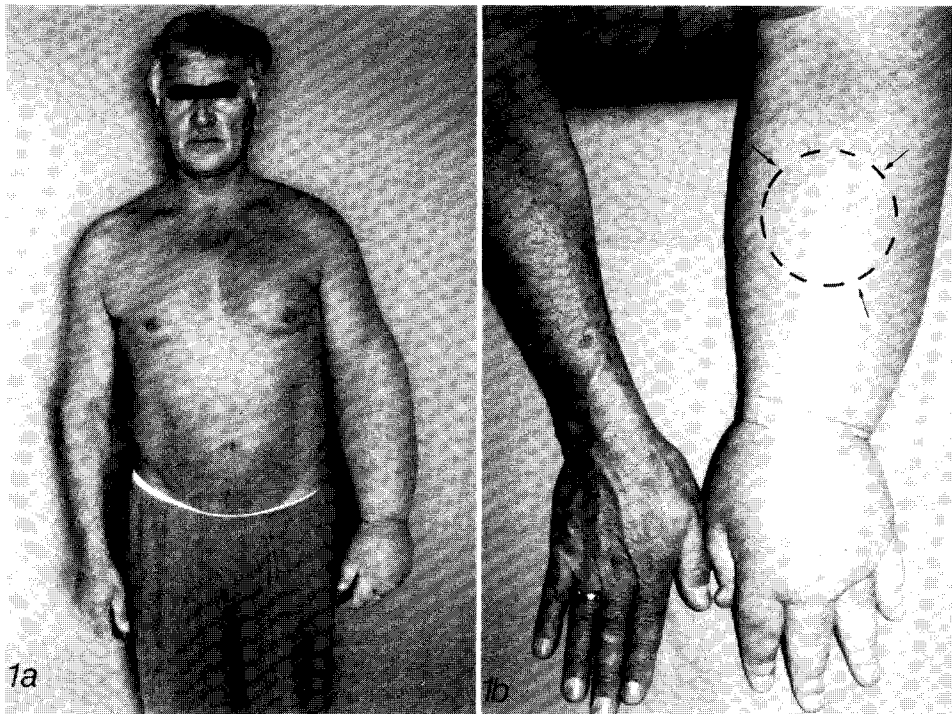


Fig. 1. (a) Clinical appearance of severe lymphedema of the left arm and pectoral region. (b) Site of location of the surface coil for obtaining the ^{31}P MR spectra (arrow).

Magnetic resonance (MR) and computer tomography (CT) are noninvasive methods for imaging and examining the internal milieu of intact tissues (1). ^{31}P MR spectroscopy also provides useful *in vivo* biochemical information (2). In this

study we examined the morphological and functional state of a skeletal muscle in an adult man with a massively enlarged lymphedematous arm and the findings were compared to the normal opposite upper extremity.

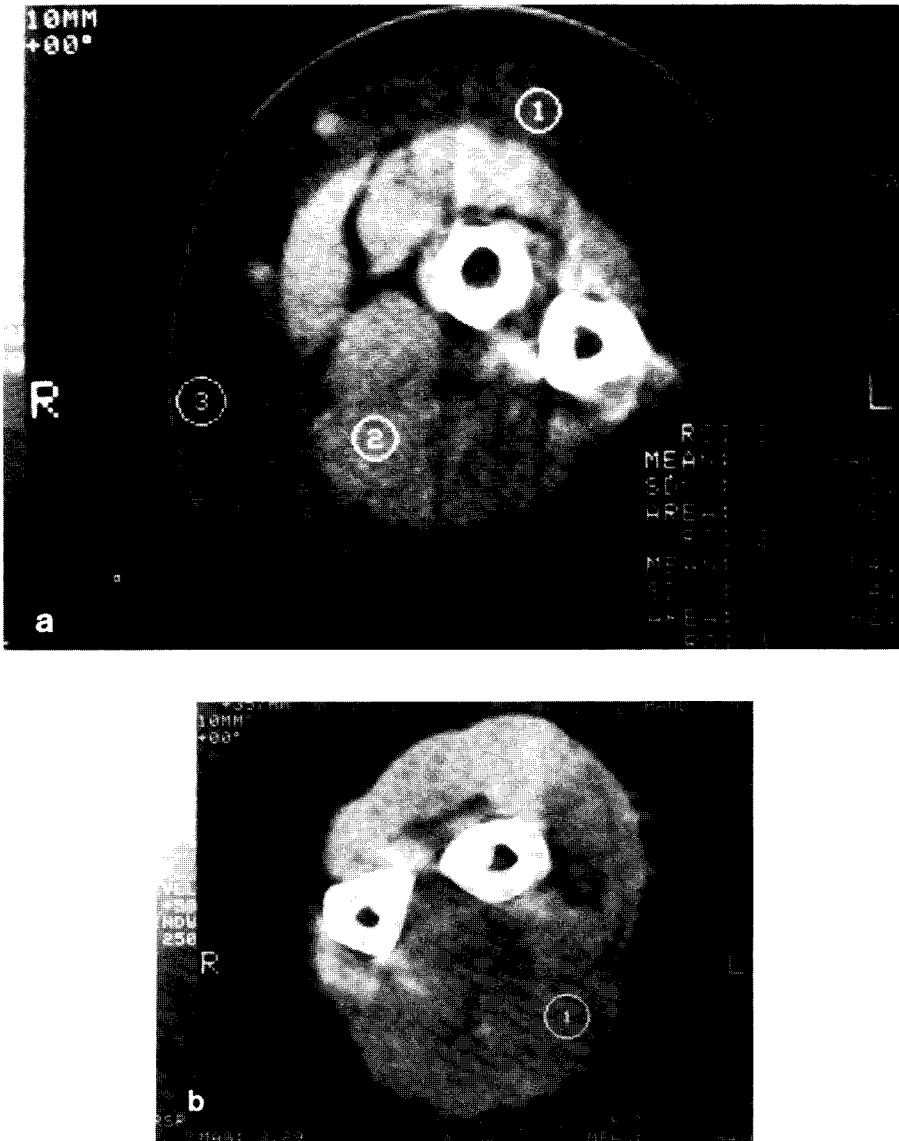


Fig. 2. CT of the lymphedematous (a) and normal opposite (b) arm. Note the tremendous enlargement of the dermis and subcutaneous compartments in the lymphedematous arm with extensive organized proliferation (1) and dilated lymphatics (3). Muscle tissue 2 in (a) and 1 in (b).

MATERIALS AND METHODS

The patient studied is a 56-year-old man with severe lymphedema since infancy (Fig. 1). After CT transaxial images and corresponding Hounsfield units were obtained, ^{31}P surface coil spectroscopy of

skeletal muscle in both arms was done. ^{31}P MR spectra were obtained using a 1.5 T GE SIGNA large bore spectrometer operating at 25.84 MHz for phosphorus. A 14cm diameter surface coil was used for spectral detection. The repetition time TR was 2000msec and a total of 254 free

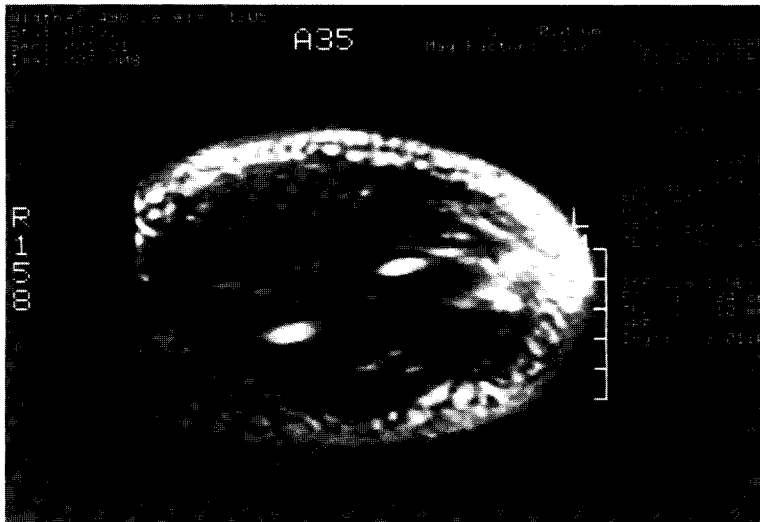


Fig. 3. Oblique transverse MR scan through the lymphedematous forearm at the level of the surface coil. T1 weighted image (SE TR=500 msec, TE=20 msec, slice thickness 10mm). In comparison to CT: tremendous enlargement of the subcutaneous lymphatics (high signal intensity) corresponding to 3 in Fig. 2a. This technique does not differentiate between the extensive organized interstitial proliferation noted by 1 in Fig. 2a and the muscle tissue. The two white spots (high signal intensity) in the center of the image correspond to the bone marrow.

induction decays (FID) were signal averaged for the spectra.

Intracellular pH for skeletal muscle was calculated using the chemical shift of the Pi signal as compared to the PCr signal, considered as reference, or:

$$K_{obs} = 3.22 + 2.51/(1 + 10^{6.803-pH})$$

where K_{obs} = the chemical shift

This equation was derived from the Henderson-Hasselbach relationship for pH and the concentration of free H^+ ions (3).

Table 1
Hounsfield Units (Mean±SD) in the Lymphedematous Compared with the Normal Arm (see Fig. 2)

	Lymphedema	Normal
Muscle	+54.47±4.62	+64.09±4.57
Interstitial Space	+33.96±3.91	-
Subcutaneous Space	-46.60±13.57	-

RESULTS

CT images of the studied region in the lymphedematous and normal arms are shown in Figs. 2a and 2b, respectively. The corresponding Hounsfield units are shown in Table 1.

The MR weighted T_1 image is shown in Fig. 3. and the ^{31}P MR spectra of skeletal muscle in the lymphedematous as compared with the normal arm are shown in Figs. 4a, 4b, respectively.

The chemical shift of the Pi signal relative to the PCr set at 0 p.p.m. was 5.214 p.p.m. in the lymphedematous arm and in the normal arm was 4.869 p.p.m. The calculated value for muscle pH in the lymphedematous arm was 7.43 as compared to 7.11 in the normal arm. From an energy point of view, there were no differences between the skeletal muscles of the two arms; they are both characterized by a PCr/Pi ratio of 13:1.

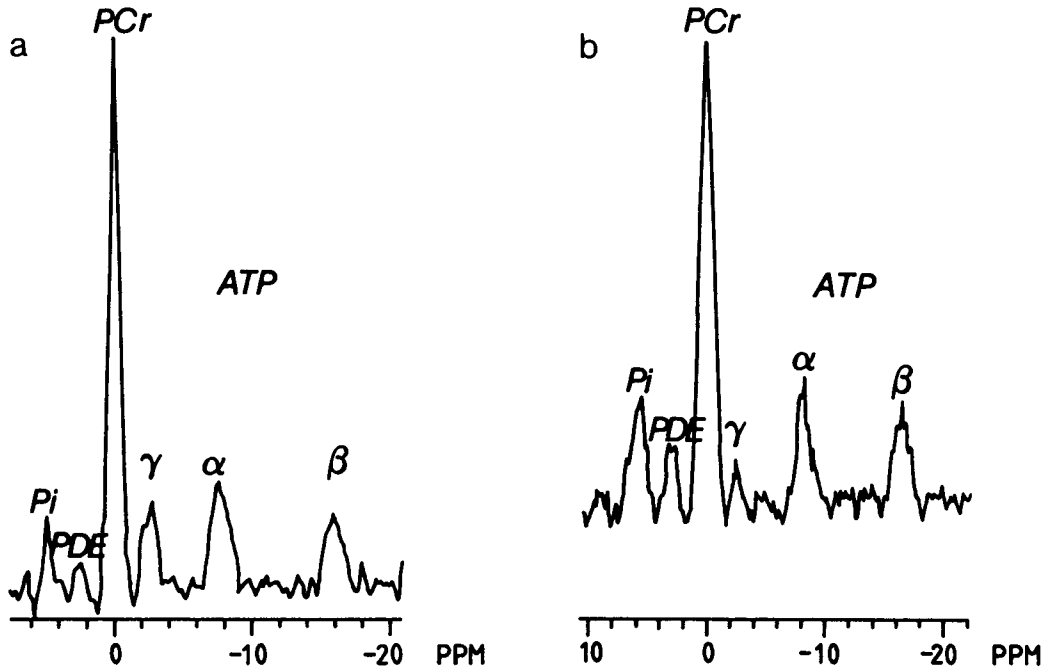


Fig. 4. ^{31}P spectra of the normal muscle (a) as compared with that in the lymphedematous arm (b). The spectra demonstrate the resonance corresponding to PCr (phosphocreatine), Pi (inorganic phosphate), PDE (phosphodiester), and α - β - γ -ATP (adenosinetriphosphates).

COMMENTS

Blockage of lymph drainage produces distal fluid accumulation with distension not only of residual lymphatics (mainly cutaneous and subcutaneous) but also adjacent tissue spaces. The "solid" part of the swelling results from fibroblastic ingrowth. The ^{31}P MR spectra of the lymphedematous skeletal muscle is notably different from normal and yields a calculated pH that is distinctly alkaline in comparison to the markedly acidic normal muscle. Corroboration of these findings and their clinical significance await further study.

REFERENCES

1. Kiricuta, IC, D Demco, V Simplaceanu: The state of water in normal and tumor tissues. *Arch. Geschwulstforsch.* 42 (1973), 214-216.
2. Gadian, DG: *Nuclear Magnetic Resonance and its Applications to Living Systems*. Clarendon Press, Oxford (1982).
3. Dhasmana, JP, SB Digerness, JM Geckle, et al: The effect of adenosine deaminase inhibitors on the heart's functional and biochemical recovery ischemia: A study utilizing the isolated rat heart adapted to ^{31}P NMR. *J. Cardiovasc. Pharmacol.* 5 (1983), 1040-1047.

I.C. Kiricuta, M.D., Ph.D.
 Strahlentherapie Klinik
 University of Würzburg
 Josef Schneider Str. 11
 8700 Würzburg
 WEST GERMANY